جَائِزَة اَلْحُسَيْن بْن عَبْدِ اَللَّهِ اَلثَّانِي لِلْعَمَلِ اَلتَّطَوُّعِيّ
AL HUSSEIN BIN ABDULLAH II AWARD FOR VOLUNTARY WORK

النادي الطبي
Medical Club

General Surgery

Subject: Nodular thyroid disease

Group no:

Done by: Aishah Khaled

هَذَا خَلْقُ اللَّهِ فَأَرُونِي مَاذَا خَلَقَ الَّذِينَ مِن دُونِهِ ۚ بَلِ الظَّالِمُونَ فِي ضَلَالٍ مُّبِينٍ

NODULAR THYROID DISEASE

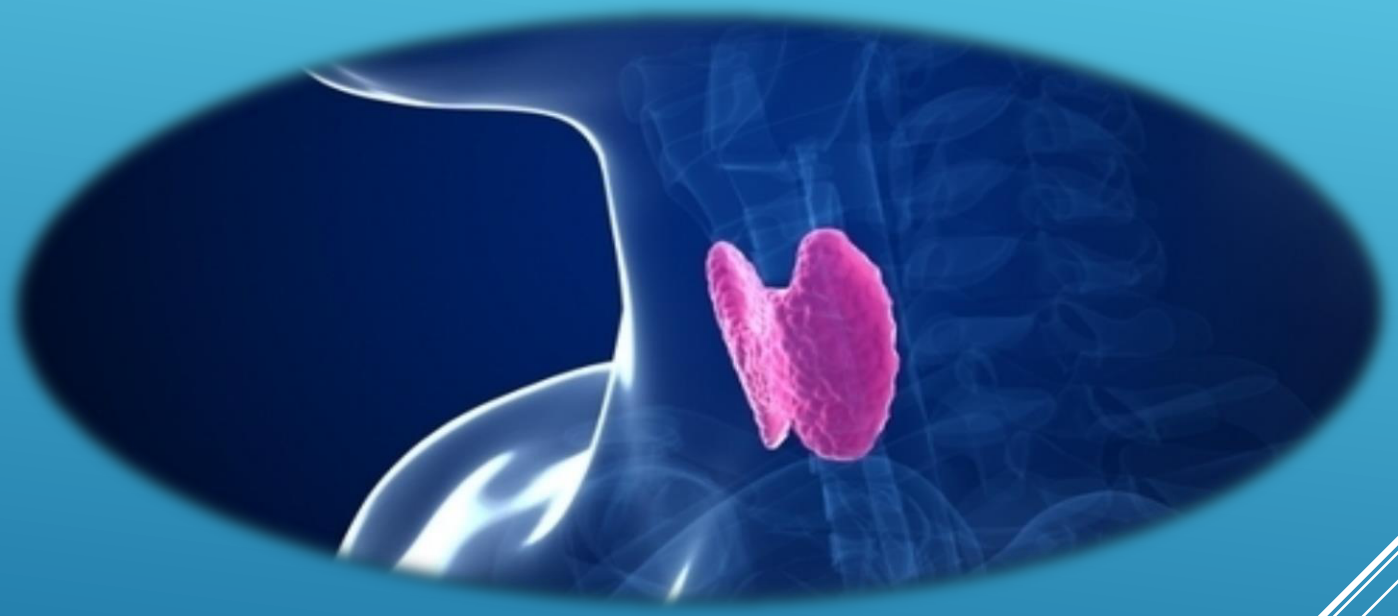

Dr. Sohail Bakkar

Asst. Prof. of Endocrine Surgery

The Hashemite University

مَن تعسّرت أُموره فَليلزَم :

{ وَقُلْ رَبِّ أَدْخِلْنِي مُدْخَلَ صِدْقٍ وَأَخْرِجْنِي مُخْرَجَ صِدْقٍ وَاجْعَلْ لِي مِنْ لَدُنْكَ سُلْطَانًا نَصِيرًا } .

أمَر اللهُ بها نبيّه ﷺ فخرَج مِن مكّة آمِناً إلى المدينة لم يمسه سوء .. وعادَ إليها فاتِحًا !
إن الدعاء فوق سلطة الواقع و فوق ظاهر الأسباب .. فالهج به و اليقين يملأ الفؤاد ..

- A thyroid nodule occurs in 5-10% of general population
- more common among women than men

* Thyroid nodule: a sonographically discrete nodule located within thyroid parenchyma (depend on US)

A thyroid nodule can be simply defined as a neck lump in the location of the thyroid gland that moves with the gland upon swallowing. Only tracheal sarcomas, parathyroid carcinomas and abnormal lymph nodes adherent to the thyroid gland can be mistaken for a thyroid nodule on physical examination, and these are uncommon. But because not every palpable thyroid lump proves to be a discrete lesion, a thyroid nodule is more accurately defined as a discrete intrathyroid lesion that is radiographically distinct from its surrounding thyroid parenchyma.

nodule

Not every lump that is located in area of thyroid gland that moves with thyroid gland upon swallowing is a thyroid nodule. (most likely is a thyroid nodule but not necessarily), it could be abnormal L.N, Asymmetrical thyroiditis, tracheal sarcoma, Parathyroid carcinoma (rarely)

↳ only carcinoma (not adenoma) could occassionally present as palpable neck lump

- To approach a thyroid nodule, you have to determine the functional status of thyroid gland
  Is the patient euthyroid, hypothyroid or thyrotoxic
- Thyrotoxicity: elevated of circulating T3, T4 along with suppressed TSH (negative feedback)

Thyroid nodular disease is common in clinical practice and is more common among females. Its prevalence largely depends on the population being evaluated and the detection method used. In adults, the prevalence of palpable thyroid nodules is around 5%, whereas the prevalence of non-palpable ones (incidentally discovered on imaging studies) is much higher; a prevalence as high as 76% has been reported with the use of high resolution ultrasonography. The most important aspect of thyroid nodular disease is its nature. The risk of malignancy per patient is equal for both palpable and non-palpable nodules. It is relatively low in adults (5%-15%), however, it is far greater in children (25%).

Causes of high levels of T3, T4 in blood (Thyrotoxicosis)
- 1. hyperfunctional thyroid gland as diffuse toxic goiter (Graves)
- 2. cellular damage of thyroid gland with spillage of thyroid hormones into blood (thyroiditis → Autoimmune as Hashimoto or post RS viral infection)

The most common palpable thyroid nodule is the prominent/dominant nodule of multinodular goiter (MNG). A true solitary nodule is less common. A true solitary thyroid nodule represents an adenoma in 80% of cases with the most common adenoma being a follicular adenoma, a carcinoma in 10% of cases and a benign condition in the remaining 10% of cases. Benign conditions include a colloid nodule/cyst, thyroiditis and fibrosis.

أَسْتَغْفِرُ اللهَ العَظِيمَ ♡

Factors that increase the likelihood of a thyroid nodule being malignant include:

1. Male sex. Despite thyroid nodular disease and cancer being more common in females; a thyroid nodule in a male is more likely to be malignant.
2. The extremes of age. The likelihood of malignancy is higher in nodules found in patients younger than 20 years or older than 60 years than those found in patients between 20 and 60 years of age.
3. A true solitary nodule as opposed to the dominant nodule of MNG. In patients with multiple nodules, the cancer rate per nodule decreases in a manner proportional to the number of nodules present. However, the overall cancer rate per patient is equal to that of patients with a solitary nodule (5%-15%). In other words, the likelihood of cancer per patient is independent of the number of nodules present. This contradicts the commonly held belief that the presence of multiple nodules reduces the likelihood of
4. Fixation. The only physical characteristic of a thyroid nodule indicative of malignancy is fixation.
5. Rapid/substantial growth. Although growth is the natural history of both benign and malignant nodules. Rapid growth is in favor of the latter, particularly anaplastic carcinoma.

6. Associated cervical lymphadenopathy.

7. Hoarseness of voice (dysphonia), particularly in case of a small lesion.

8. History of radiation exposure, (ionizing radiation but not diagnostic or cosmic radiation), particularly as a child. History of radiation exposure has a therapeutic implication as well when considering the extent of surgery in the setting of thyroid nodular disease and/or differentiated thyroid cancer; since the entire thyroid gland was certainly exposed to the radiation, a total thyroidectomy should be performed.

9. A background of Hashimoto's thyroiditis. A nodule appearing in a patient with Hashimoto's thyroiditis could be a lymphoma or a PTC.

10. A cold (non-functioning) nodule as opposed to a hot (hyperfunctioning) or a warm (normally functioning) one.

11. Personal and/or family history of thyroid cancer or a thyroid cancer syndrome.

12. Obesity. Obesity is an independent risk factor for thyroid cancer. However, the potential mechanisms underlying the association between BMI and thyroid cancer require further study. This association has considerable public health implications especially that the prevalence of obesity is markedly increasing worldwide.

لا إِلَـــــهَ إِلَّا أَنـــــتَ سُبحانَـــكَ
إِنِّي كُنتُ مِنَ الظَّالِمِيـــــنَ.

Diagnostic evaluation of a thyroid nodule

The first step in approaching a patient with a thyroid nodule is to assess the functional status of the thyroid gland by performing a thyroid function test (TFT). Only hyperthyroid patients (low TSH) require a thyroid scan to assess the functional status of the nodule itself. If the thyroid scan reveals a hot nodule then this is almost invariably benign. It is typically a solitary toxic adenoma that should be treated by thyroid lobectomy; fine needle aspiration with cytopathologic analysis (FNAC) would not be useful. Ultrasound (US) and FNAC are indicated in euothyroid and hypothyroid patients. In these patients there is no added benefit of assessing the functional status of the nodule itself. Therefore, a thyroid scan should not be performed routinely to evaluate the functional status of a thyroid nodule in the era of US and FNAC. Routine measurement of serum thyroglobulin (TG) is not part of the initial diagnostic evaluation of a thyroid nodule as it lacks specificity for thyroid cancer (elevated in most thyroid disease). However, measuring serum levels of calcitonin may be useful. It may help detect medullary thyroid carcinoma (MTC) at an early stage.

What are sonographic features that increase possibility of malignancy?

1. Irregular margin
2. taller than wide orientation (proliferating malignant cells)
3. microcalcification (reflect presense of Psamoma bodies)

↑ T4
↓ TSH
↓
Thyrotoxic condition
↓
Do thyroid scan

ATA guidelines:

THYROID
Volume 19, Number 11, 2009
© Mary Ann Liebert, Inc.
DOI: 10.1089/thy.2009.0110

RESEARCH ARTICLE

Revised American Thyroid Association Management Guidelines for Patients with Thyroid Nodules and Differentiated Thyroid Cancer

The American Thyroid Association (ATA) Guidelines Taskforce on Thyroid Nodules and Differentiated Thyroid Cancer

David S. Cooper, M.D.[1] (Chair)*, Gerard M. Doherty, M.D.,[2] Bryan R. Haugen, M.D.,[3] Richard T. Kloos, M.D.,[4] Stephanie L. Lee, M.D., Ph.D.,[5] Susan J. Mandel, M.D., M.P.H.,[6] Ernest L. Mazzaferri, M.D.,[7] Bryan McIver, M.D., Ph.D.,[8] Furio Pacini, M.D.,[9] Martin Schlumberger, M.D.,[10] Steven I. Sherman, M.D.,[11] David L. Steward, M.D.,[12] and R. Michael Tuttle, M.D.[13]

Initially published in 2006 (revised in 2009, new revision expected in 2015)

ATA guidelines provide comprehensive approach to thyroid nodules.

Algorithm for the evaluation of patients with one or more thyroid nodules:

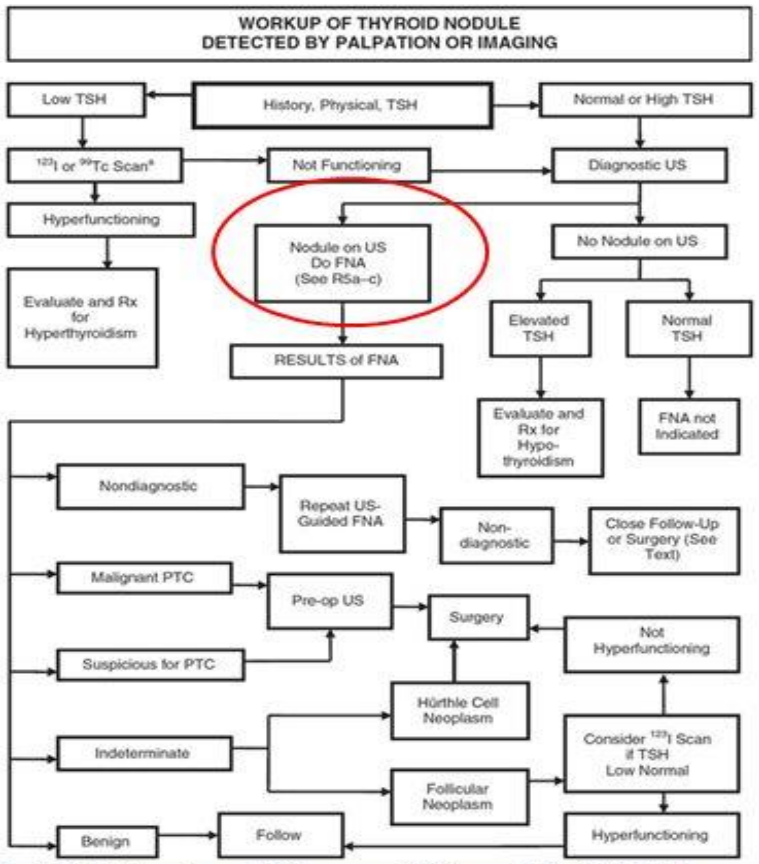

Cooper DS, Doherty GM, Haugen BR, Kloos RT, Lee SL, Mandel SJ, Mazzaferri EL, McIver B, Pacini F, Schlumberger M, Sherman SI, Steward DL, Tuttle RM. Revised American Thyroid Association management guidelines for patients with thyroid nodules and differentiated thyroid cancer. American Thyroid Association (ATA) Guidelines Taskforce on Thyroid Nodules and Differentiated Thyroid Cancer .Thyroid. 2009 Nov;19(11):1167-214.

يأخذ الشخص فيها مادة , تؤخذ من قبل الغدة الدرقية فقط وتضيئها

← أخذت المادة بكميات معتدلة

Uptake (0.4 - 4 %)

↑ Uptake

> 4 %

Diffuse toxic goiter → Graves

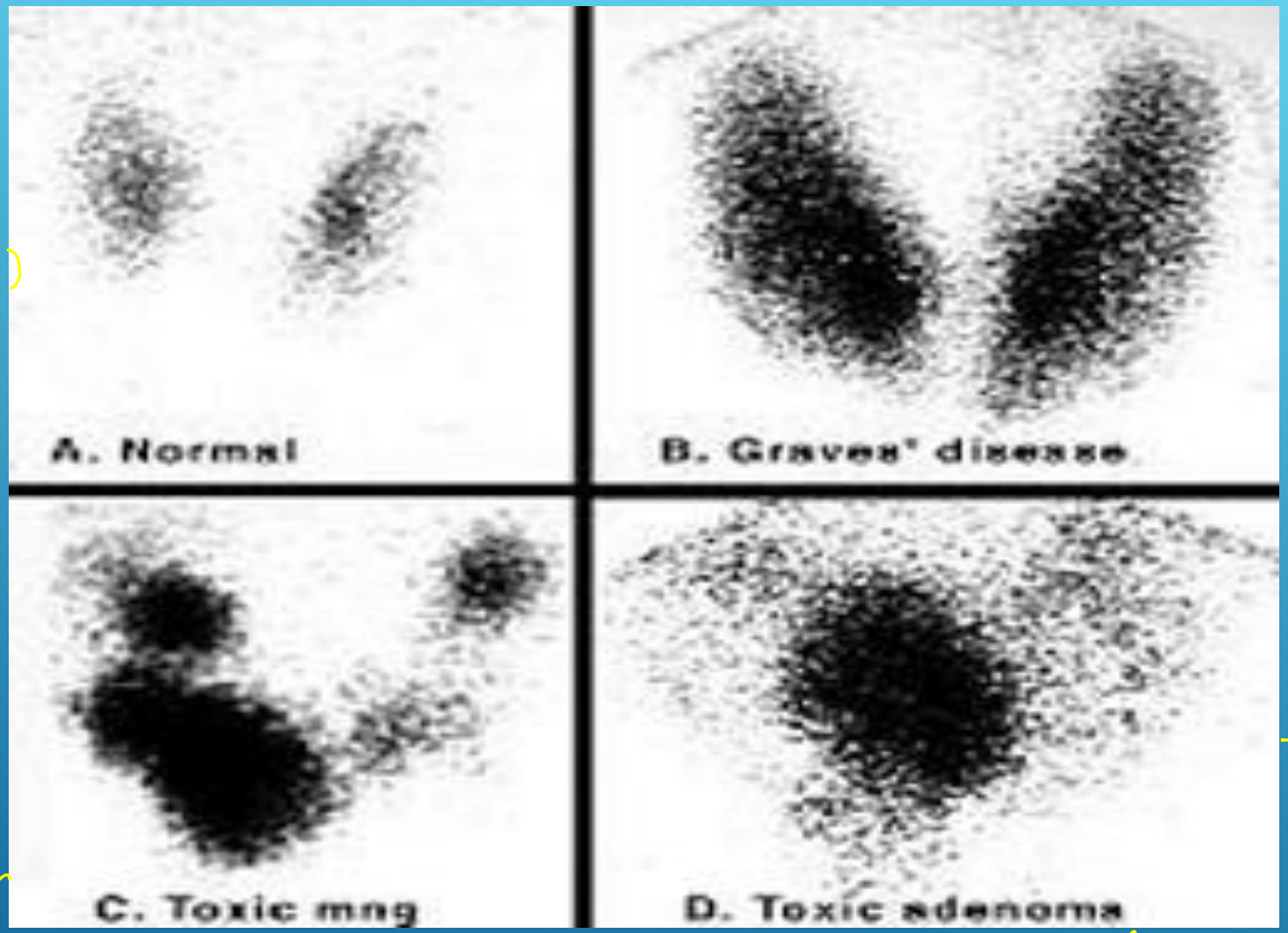

↑ Uptake

في معظم أجزاء الغدة

not diffuse ولكن

(على شكل كتل)

Toxic multinodular goiter

↑ Uptake

not diffuse

→ Solitary toxic adenoma

* حالة Thyroiditis يكون ↓TSH / ↑T3,T4 وما كان في تلوّن بالصورة negative

لإنه الـ cells متكسرات , فأخذت المادة وطلعتها مباشرة ما بينت على الصورة

cell destruction

Treatment

* Toxic multinodular goiter → total resection of thyroid gland

ما بنفع معه اليود المشع ، لإنه في كتل متعددة بأحجام متعددة و لكل منهم قابلية مختلفة بامتصاص اليود

بالتالي في كتل رح تمتص وكتل لا ، وما بتعالج المريض فالحل Total resection

* Solitary toxic adenoma → Iodine or partial resection of thyroid (that contain adenoma)

لإنها الوحيدة اللي بتشتغل بكثرة ، أما باقي ال thyroid مثبط ← negative feedback inhibition

* Graves → Iodine, medication, surgery

اليود بنفع معهم لإنه الكتل متجانسة وتمتص اليود كلها ، ولكن اليود مش لكل المرضى لإنه ممكن يعمل subfertility

أو unkown teratogenic وممكن يعمل leukemia, lymphoma وممنوع اللي عنده exophthalmos لإنه بزيد ال exophthalmos

ولو كان في كتلة نتجه للجراحة حتى نستأصلها ونعرف إذا benign or malignant

So, thyrotoxicosis → Do thyroid scan

if Euthyroid (normal thyroid function) or hypothyroid → there is no need for thyroid scan

Do US guided for FNA

Table 1. The Bethesda system for reporting thyroid cytopathology- diagnostic categories
I. Nondiagnostic or unsatisfactory
II. Benign
III. Atypia of undetermined significance or follicular lesion of undetermined significance
IV. Follicular neoplasm or suspicious for a follicular neoplasm
V. Suspicious for malignancy
I. Malignant

FNA → Removing cells to study under microscope

Bethesda diagnostic category			Risk of malignancy	Usual management
I	Nondiagnostic or unsatisfactory طريقة أخذ العينة ليست كافية للوصول لنتيجة	Cyst fluid only Virtually acellular specimen Other (obscuring blood, clotting artifact, etc.)	1% to 4%	Repeat FNA with ultrasound guidance
II	Benign 97% – 99% is benign	Consistent with a benign follicular nodule (includes adenomatoid nodule, colloid nodule, etc.) Consistent with lymphocytic (Hashimoto) thyroiditis in the proper clinical context Consistent with granulomatous (subacute) thyroiditis Other	0% to 3%	Clinical follow-up
III	Atypia of undetermined significance or follicular lesion of undetermined significance		5% to 15%	Repeat FNA
IV	Follicular neoplasm or suspicious for a follicular neoplasm	Specify if Hurthle cell (oncocytic) type	15% to 30%	Surgical lobectomy
V	Suspicious for malignancy	Suspicious for papillary carcinoma Suspicious for medullary carcinoma Suspicious for metastatic carcinoma Suspicious for lymphoma Other	60% to 75%	Near-total thyroidectomy or surgical lobectomy
VI	Malignant	Papillary thyroid carcinoma Poorly differentiated carcinoma Medullary thyroid carcinoma Undifferentiated (anaplastic) carcinoma Squamous cell carcinoma Carcinoma with mixed features (specify) Metastatic carcinoma Non-Hodgkin lymphoma Other	97% to 99%	Near-total thyroidectomy

ممكن خلال follow up تزيد بالحجم
ولكن زيادة الحجم تحدث بال benign & malignant

If increase >20% of transverse diameter this is significant, we have to repeat FNA (maybe tranfer to malignant)

لو عنده كتلة وحدة بالغدة وطلعت IV
بنشيل النص، لو المريض عنده hypo
hashimoto أو عنده كتل صغيرة
أخرى بالجناح الآخر أو
FHx of thyroid cancer
أو تعرض لإشعاع
بنشيلها كلها

References

Moon HJ, Kwak JY, Kim MJ, Son EJ, Kim EK 2010 Can vascularity at power Doppler US help predict thyroid malignancy? Radiology. 255:260-269.

Rosario PW, da Silva AL, Borges MA, Calsolari MR 2015 Is Doppler ultrasound of additional value to gray-scale ultrasound in differentiating malignant and benign thyroid nodules? Arch Endocrinol Metab. 59:79-83.

Brito JP, Gionfriddo MR, Al Nofal A, Boehmer KR, Leppin Al, Reading C, Callstrom M, Elraiyah TA, Prokop LJ, Stan MN, Murad MH, Morris JC, Montori VM 2014 The accuracy of thyroid nodule ultrasound to predict thyroid cancer: systemic review and meta-analysis. J Clin Endocrinol Metab 99:1253-1263.

Kim ES, Nam-Goong IS, Gong G, Hong SJ, Kim WB, Shong YK 2003 Postoperative findings and risk for malignancy in thyroid nodules with cytological diagnosis of the so-called “follicular neoplasm”. Korean J Intern Med. 18:94–97.

Thyroid carcinomas are classified according to their cell of origin into those of follicular cell origin (95%) and those of parafollicular cell origin. The former include: papillary, follicular, Hürthle cell, insular, large cell and anaplastic carcinomas. The latter include medullary carcinomas. Thyroid carcinomas of follicular cell origin are in turn classified according to their degree of differentiation into well, poorly and undifferentiated lesions. Together poorly and undifferentiated cancers account for 2% to 5% of all cancers of follicular cell origin. These may arise de novo or as a result of progression (dedifferentiation) of well differentiated tumors.

Thyroid carcinomas of follicular cell origin	
Papillary carcinoma Follicular carcinoma Hürthle cell carcinoma	Well differentiated
Insular carcinoma Large cell carcinoma	Poorly differentiated
Anaplastic carcinoma	Undifferentiated

PTC is the most common but least aggressive carcinoma of the thyroid gland. It is more common in iodine sufficient areas of the world and is the thyroid cancer that most strongly correlates with radiation exposure. The Chernobyl disaster (the worst nuclear power plant accident in history, 1986) was followed by an increase in the incidence of thyroid cancer in the areas exposed to high levels of fall out. The tumors discovered were virtually all of the papillary carcinoma type. The mean age at presentation is between 30 and 40 years. It is also the most common thyroid cancer in children.

PTC is multicenteric in up to 80% of cases. Multicentricity, however, does not adversely affect prognosis. It only influences the rationale behind a total thyroidectomy in case of PTC. Spread is typically lymphatic rather than hematogenous. Children are more likely to be node positive than adults. Yet, unlike other epithelial cancers lymphatic spread in PTC does not seem to adversely cause-specific mortality. The most common site of hematogenous spread, if it occurs, is the lungs.

PTC was so called as it was originally described with a papillary growth pattern. It can, however, have a mixed papillary and follicular growth pattern (the papillary-follicular variant) or even an exclusive follicular growth pattern. Therefore, the diagnosis of PTC is based on the nuclear features of neoplastic cells rather than architectural features. The follicular variant of PTC is its most common histological variant. Other histological variants of PTC include: the oncocytic, the diffuse sclerosing, the columnar cell and the tall cell variants. The tall cell variant is very rare but is the most aggressive variant. It was so called as the height of the malignant cell is three times its width.

Features of malignant cells in PTC on FNA include:

1. **Optically clear nuclei**. The nuclei of malignant cells contain finely dispersed chromatin, therefore, appear empty and are called "optically clear nuclei“. These are often referred to as "orphan Annie eye nuclei" due to their resemblance to the eyes of little orphan Annie (a daily American comic strip popular in the period of 1894-1968).

2. **Nuclear crowding/overlap**

3. **Intranuclear cytoplasmic inclusions**. These are characteristic of PTC but may also be seen in medullary thyroid carcinoma.

4. **Nuclear envelope irregularities/nuclear grooves**. These represent infoldings of the nuclear envelope created by adherence of chromatin to the nuclear envelop.

5. **Psammoma bodies.** Represent calcified clumps of malignant cells.

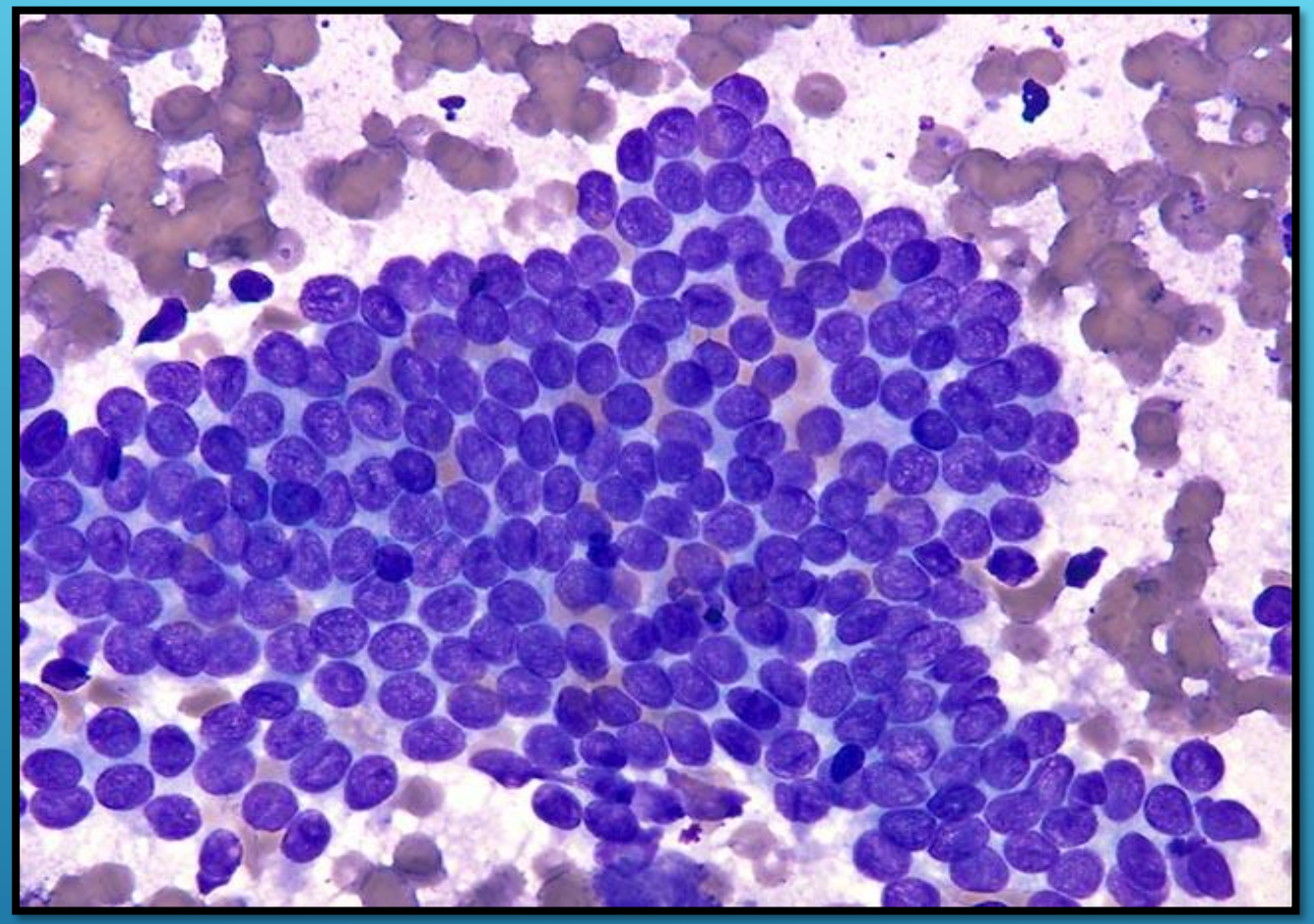

The figure demonstrates two important features of papillary thyroid carcinoma: optically clear nuclei and nuclear crowding.

overlapping

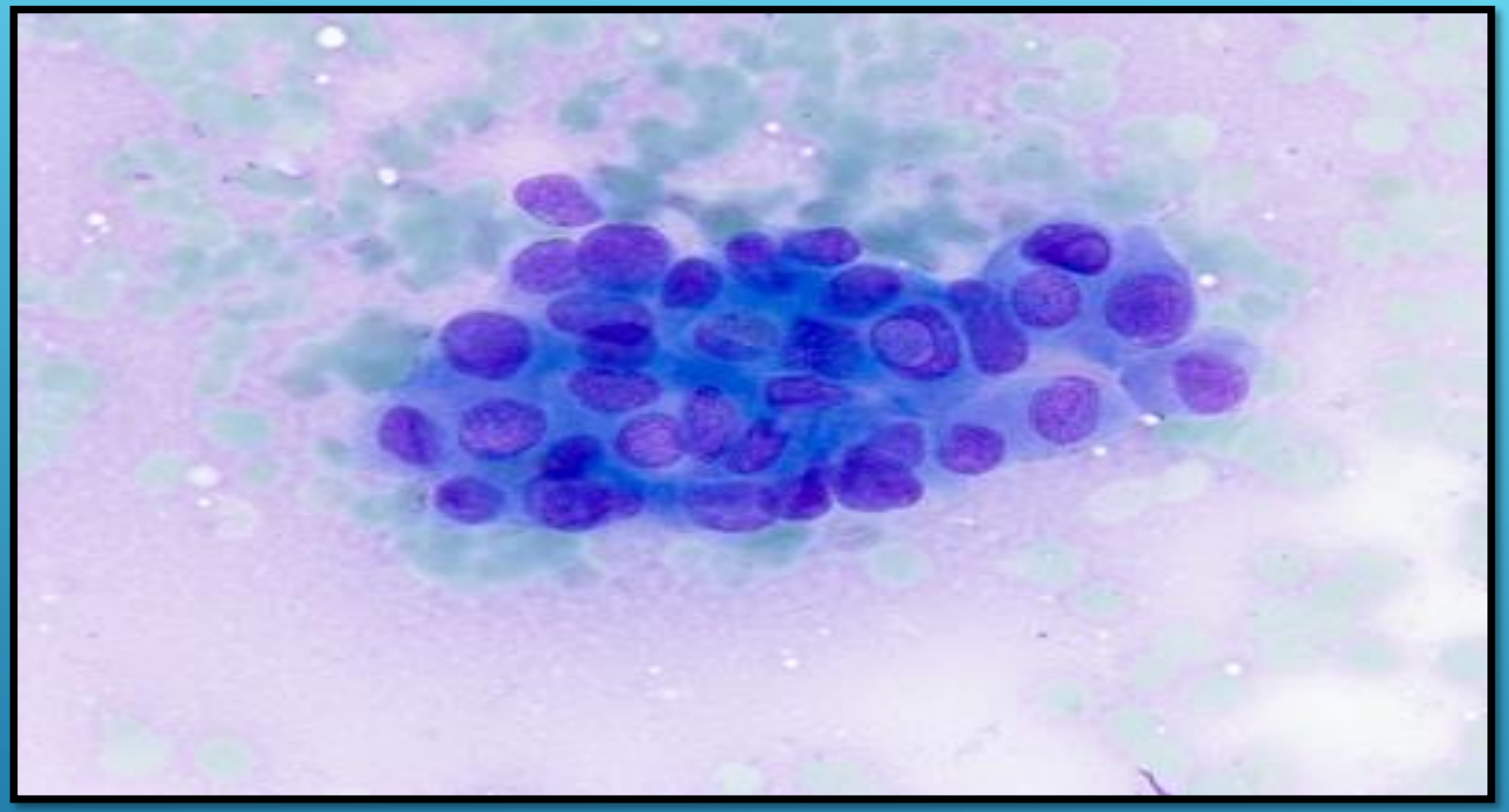

Papillary thyroid carcinoma (Intranuclear cytoplasmic inclusions)

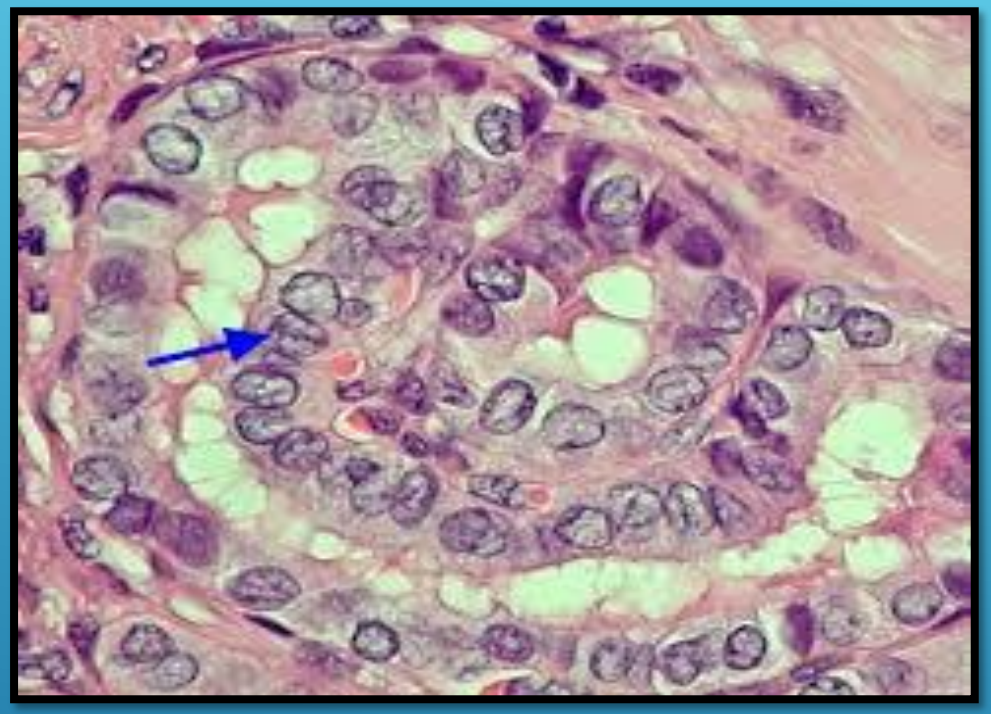

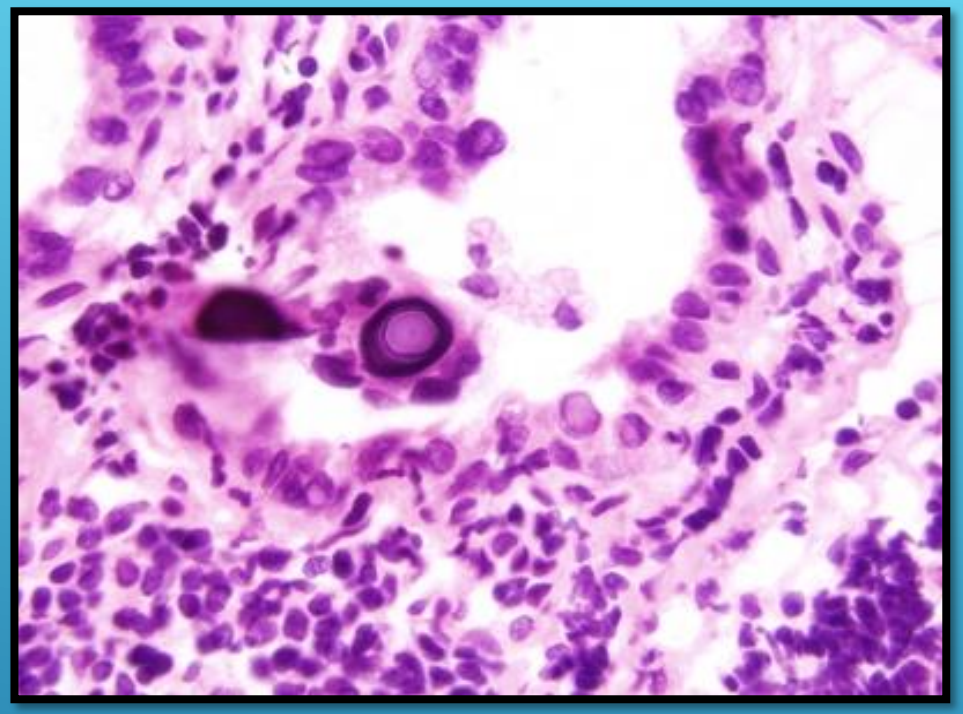

Papillary thyroid carcinoma: a. Nuclear groove (blue arrow). b. Psammoma body.

ridge on nucleur envelop

يمثل تكتل من الخلايا السرطانية
مع الكالسيوم

Papillary microcarcinoma → we can differentiate it by cytologic examination

Papillary microcarcinoma is papillary carcinoma that is equal to or less than 1cm in size. It is typically discovered incidentally in a surgical specimen (such a thyroid lobe following total thyroid lobectomy performed for some other indication) or while performing a thyroid ultrasound exploration. Papillary microcarcinoma despite being malignant by definition does not have a malignant behavior. Therefore, its treatment is not similar to that of papillary carcinoma. Total thyroid lobectomy is considered sufficient if the lesion is single, low risk and there is no history of radiation exposure. Conservative management (observation) has been recently recommended by some; further proof of its indolent nature.

The 10 year survival rate of papillary microcarcinoma is 100%.

Follicular thyroid carcinoma (FTC)

We can't diagnose it based on cytology, we can only diagnose it based on histology to demonstrate capsular, vascular invasion

FTC is the second most common thyroid cancer. It is more common in iodine deficient areas of the world with the mean age at presentation being 50 years. Supplementing diet with iodine has decreased the incidence of FTC and has relatively increased the incidence of PTC. FTC is the thyroid cancer most commonly associated with MNG and is rarely associated with radiation exposure.

FTC is usually solitary (unifocal). Spread is typically hematogenous with the most common site of distant spread being bone followed by the lungs. Lymphatic spread is seen in < 10% of cases. FTCs are typically non-functional. Less than 1% are hyperfunctional.

The diagnosis of FTC is based on demonstrating capsular and/or vascular invasion on histopathologic examination of a surgically resected specimen. The distinction between follicular adenoma and carcinoma cannot be made on the basis of cytomorphology.

Therefore, a good strategy in a patient with a FNA consistent with a follicular neoplasm is to go in one of two ways.

The first is to perform at least a total thyroid lobectomy and wait for the result permanent pathology.

The second is to perform a total thyroidectomy from the start in patients with a history of radiation exposure or contralateral nodular disease.

In the former situation, if permanent pathology reveals a follicular carcinoma then completion thyroidectomy should be performed preferably within a week from the initial operation or three months later not to fall in the period of maximal scarring. Delaying completion thyroidectomy beyond six months of the initial operation has been demonstrated to be detrimental.

Occasionally, histopathologic examination may demonstrate capsular invasion without vascular invasion. This variant of FTC is known as minimally invasive FTC. As with papillary microcarcinoma minimally invasive FTC despite being malignant by definition does not have malignant behavior. Total thyroid lobectomy is, therefore, considered sufficient with no need for completion thyroidectomy, radioactive iodine ablation or TSH suppression.

The overall 10 year survival rate of invasive FTC is 85%.

THANK
YOU