Anemia

- Anemia is a pathologic state resulting in an insufficient number of erythrocytes to deliver oxygen to organs and tissues.
- Anemia can arise from blood loss, underproduction of erythrocytes, destruction of erythrocytes or a combination of these factors.
- presentation depends on the degree of anemia ,the rapidity with which anemia develops (Patients with chronic anemia are most likely asymptomatic) as well as the presence or absence of underlying end organ or vascular disease.
- Symptoms of anemia : dyspnea , decreased exercise tolerance , palpitations , lightheadedness , fatigue and syncopy.

Approach to a patient with anemia

- History taking
- Physical examination
- investigations

- CBC along with the peripheral blood smear can give valuable clues to the diagnosis
- Macrocytic , microcytic , normocytic to narrow the differential diagnosis.
- In addition to the CBC, the reticulocyte count provide clue to the diagnosis; A normal bone marrow will produce more reticulocytes in response to anemia or hypoxia. In contrast , patients with vitamin b12, folate or iron deficiency or those with marrow diseases such as myelodysplasia or aplastic anemia , Cannot produce adequate reticulocytes in response to anemia .

Peripheral Blood Smear Finding	Interpretation
Bite cells (erythrocytes with a nonstaining, clear zone)	Glucose-6-phosphate dehydrogenase deficiency
Burr cells (echinocytes; erythrocytes with a small number of spicules of uniform size and distribution on the cell surface)	Uremia
Elliptocytes (erythrocytes that are elongated, oval, or elliptically shaped)	Hereditary elliptocytosis
Macrocytes or macro-ovalocytes	Cobalamin or folate deficiency, myelodysplasia, use of antimetabolites
Microcytosis, anisopoikilocytosis	Iron deficiency
Nucleated erythrocytes	Marrow stress (hemolysis, hypoxia)
Rouleaux formation ("stacked-coin" appearance of erythrocytes)	Paraproteinemia (myeloma)
Schistocytes (irregularly shaped, jagged fragments of erythrocytes)	Microangiopathy (TTP, HUS, DIC)
Sickle cells (drepanocytes; erythrocytes with spiculated shape)	Sickle cell anemia
Spherocytes (small hyperchromic erythrocytes without central pallor)	Hereditary spherocytosis, warm autoimmune hemolytic anemia
Spur cells (acanthocytes; erythrocytes with a small number of spicules of variable size and distribution on the cell surface)	Severe liver disease
Stomatocytes (erythrocytes with a mouth-shaped area of central pallor)	Artifact, hereditary stomatocytosis
Target cells (codocytes; erythrocytes with an area of central density surrounded by pallor and then a rim of density)	Hemoglobinopathy, liver disease, splenectomy, iron deficiency
Teardrop cells (dacryocytes; cells with round main body part and an elongated end)	Fibrosis, marrow granuloma, marrow infiltration

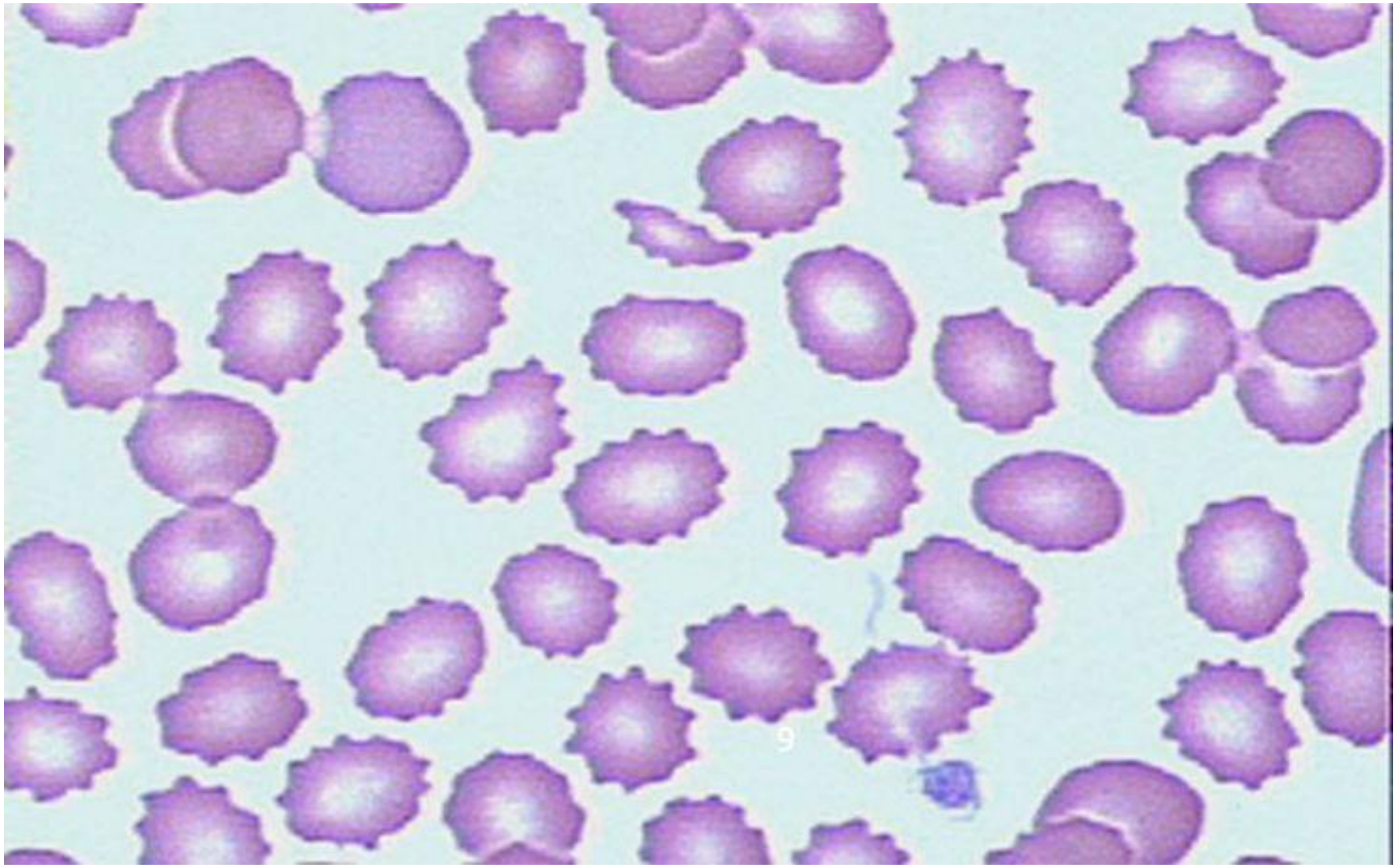

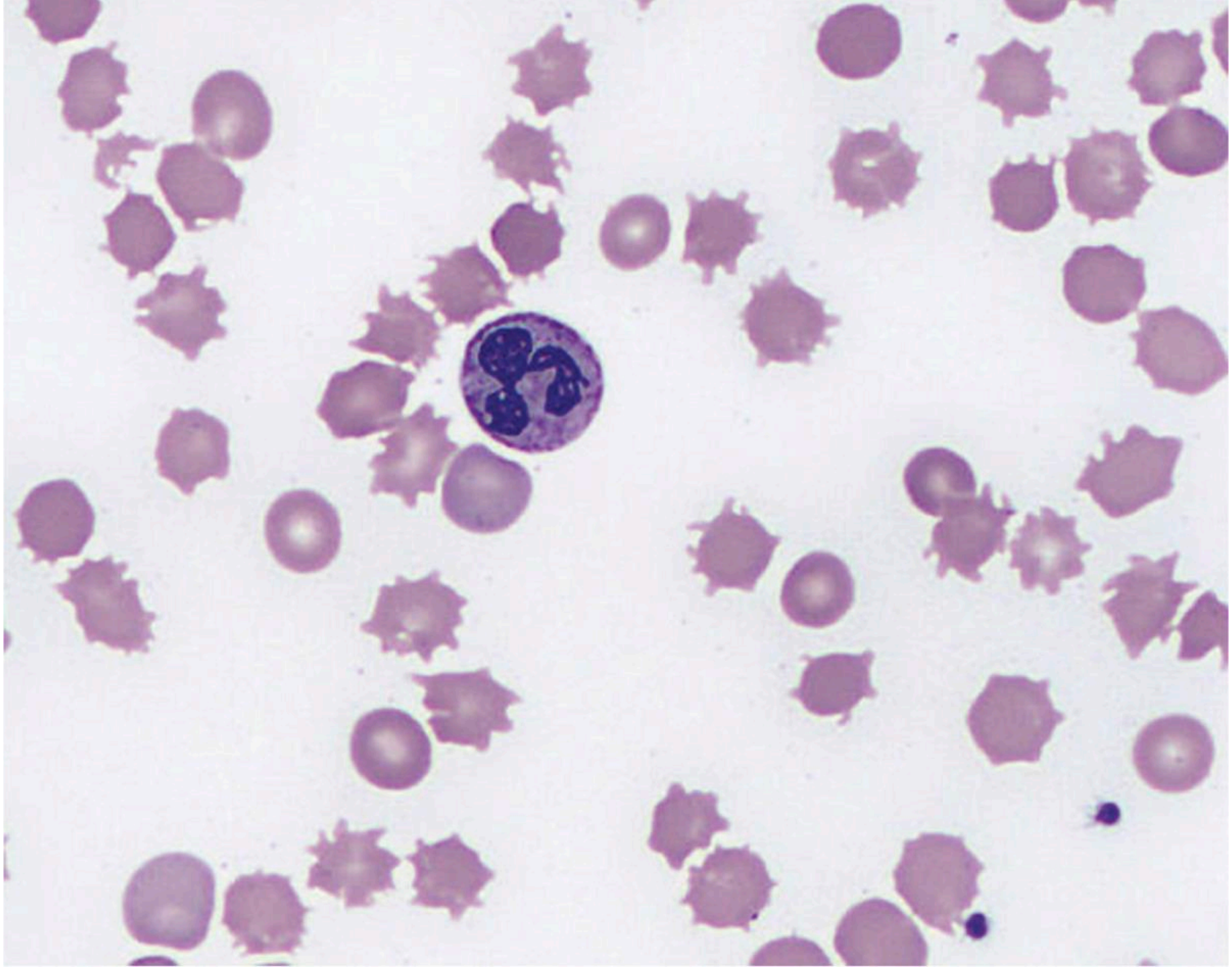

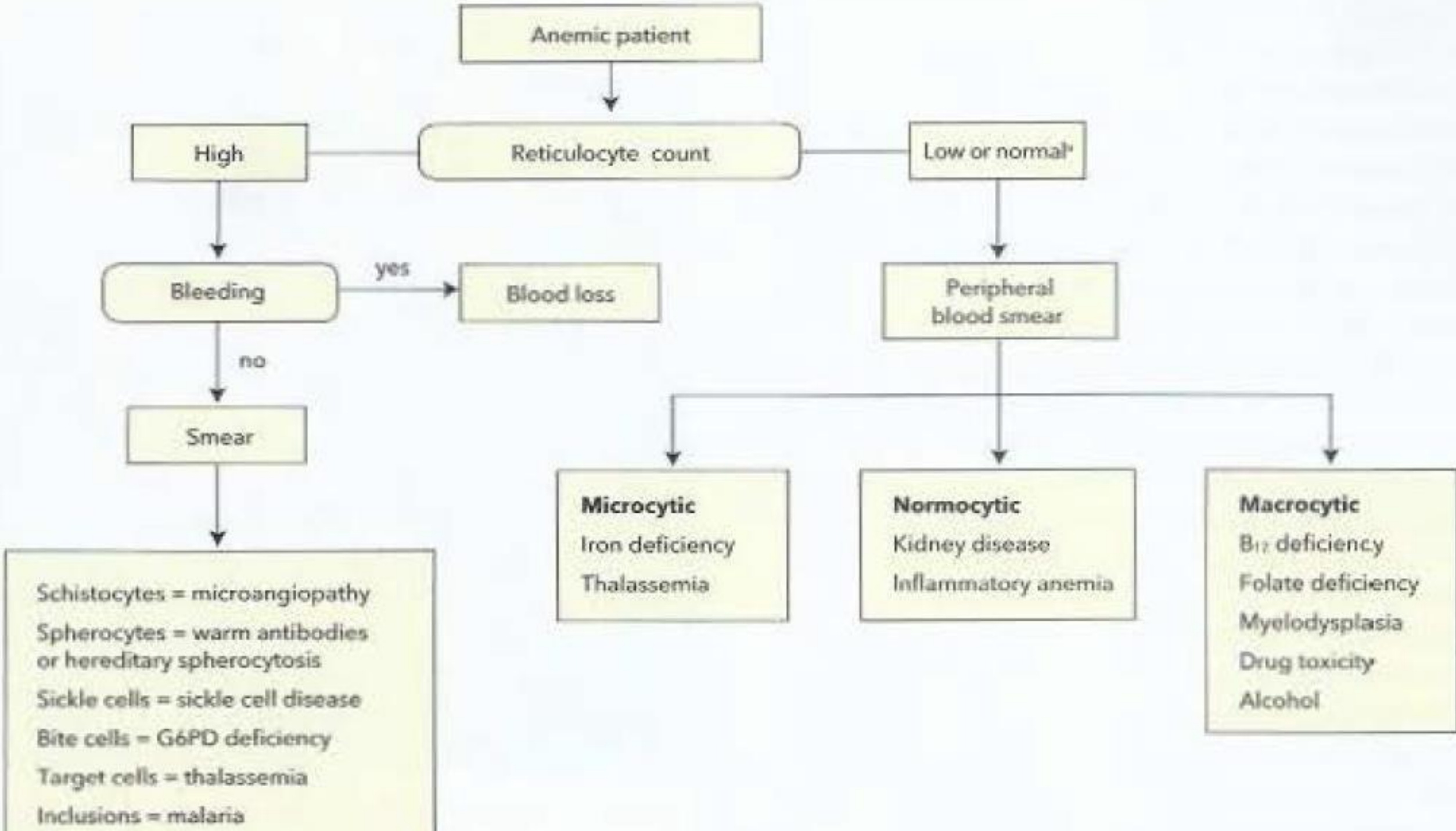
Anemic patient
Reticulocyte count
High
Low or normal
Bleeding
yes
Blood loss
no
Smear
Peripheral blood smear
Schistocytes = microangiopathy
Spherocytes = warm antibodies or hereditary spherocytosis
Sickle cells = sickle cell disease
Bite cells = G6PD deficiency
Target cells = thalassemia
Inclusions = malaria
Microcytic
Iron deficiency
Thalassemia
Normocytic
Kidney disease
Inflammatory anemia
Macrocytic
B12 deficiency
Folate deficiency
Myelodysplasia
Drug toxicity
Alcohol

- bone marrow aspirate and biopsy can be helpful in the diagnosis of anemia, especially in assessing stem cell disorders like aplastic anemia, dysmyelopoitic syndromes and acute leukemia.

- The presence of combined cytopenias increases the likelihood of a primary marrow disorder.

Anemia Due to Erythrocyte Underproduction or Maturation Defects

- Iron deficiency anemia
- Inflammatory anemia (anemia of chronic disease)
- Anemia of kidney disease
- Cobalamin (vitamin b12) deficiency
- Folate deficiency
- Thalassemias

Iron deficiency anemia

- Iron is an essential component of the hemoglobin molecule.
- In addition to its crucial role in oxygen delivery, iron is also necessary for DNA synthesis and cellular transport.
- Hepcidin is the key protein in iron regulation. It’s produced in the liver and it’s a negative regulator f iron absorption.
- Its production increases with inflammation , and decreases in hypoxia , anemia and iron deficiency.
- Hepcidin causes internalization and proteolysis of ferroportin in the gut and macrophages causing inhibition of absorption from the gut as well as inhibition of release from macrophages.

TABLE 13. Causes of Iron Deficiency Anemia
Loss of iron
Bleeding
Menstruation
Gastrointestinal bleeding (can be microscopic)
Other overt or occult blood loss
Decreased intake
Nutritional deficiency
Decreased absorption
After gastric/duodenal surgery
Celiac disease
Helicobacter pylori infection
Autoimmune atrophic gastritis
Increased iron requirements
Pregnancy
Lactation

- A low MCV , elevated RDW and a peripheral blood smear showing microcytosis with anisopoikilocytosis are virtually diagnostic of iron deficiency anemia.
- A low serum iron , elevated total iron binding capacity, low transferrin saturation (iron /total iron binding capacity *100), low serum ferririn (less than 14 ng/ml) confirm the diagnosis of iron deficiency.

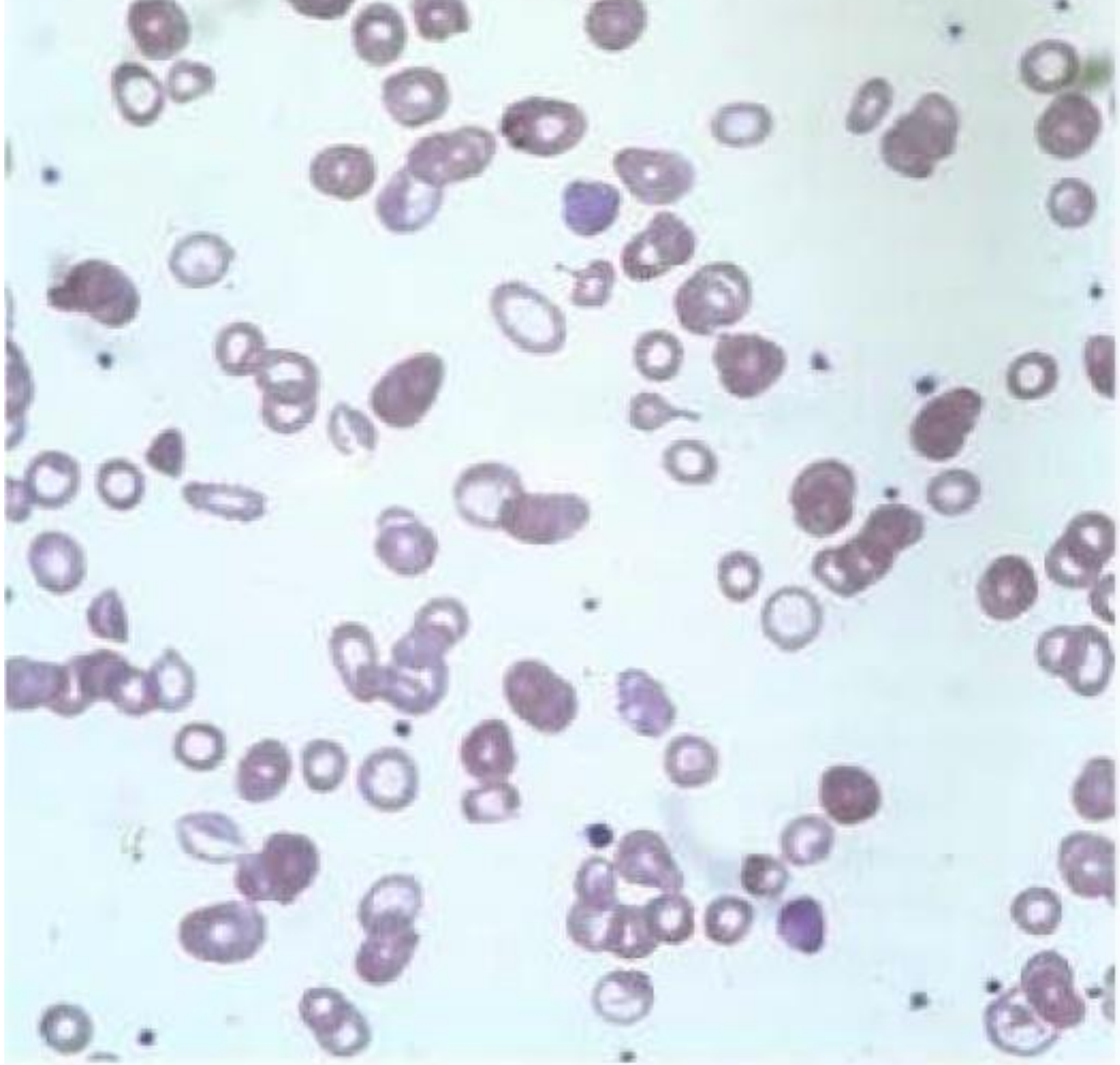

FIGURE 9. Hypochromia and microcytosis with anisopoikilocytosis in a patient with iron deficiency. Note the relatively small erythrocytes compared with the lymphocytes on the smear. Note also the abnormalities in shape and size of the

- Iron deficiency is treated with oral iron salts. Oral ferrous sulfate is the least expensive preparation with each 325 mg contains 65 mg of elemental iron.
- frequent dosing ; 2-3 times daily increase hepcidin which will interfere with iron absorption. Therefore, its better to give single daily dose or EOD.
- Iron replacement results in reticulocytosis within days , with an increase in hg concentration of 1 g/week.
- iron replacement should be continued 3-6 months after normalization of hg , to replenish iron stores.

- Parenteral iron : high iron requirements in dialysis patients , malabsorption

Inflammatory anemia

- Causes:

- Chronic infections
- Chronic rheumatological diseases
- Malignancies

** increased inflammatory mediators :

>> increased hepcidin , decreased iron absorption

>> blunt erythropoietin response to anemia

- Normochromic , normocytic >> later microcytic hypochromic may develop (hepcidin effect)
- Low reticulocyte count (erythropoietin effect)
- Elevated ferritin , low serum iron , low TIBC.

Anemia with kidney disease

- Relative deficiency of erythropoietin (synthesized in renal cortex in response to anemia and hypoxia)
- Low retic count , normocytic normochromic anemia
- Burr cells (echinocytes) in blood film in case of uremia
- Microcytic features should raise the suspicion of iron deficiency (platelets dysfunction , angiodysplasia and peptic ulcer disease which may lead to gi bleeding).

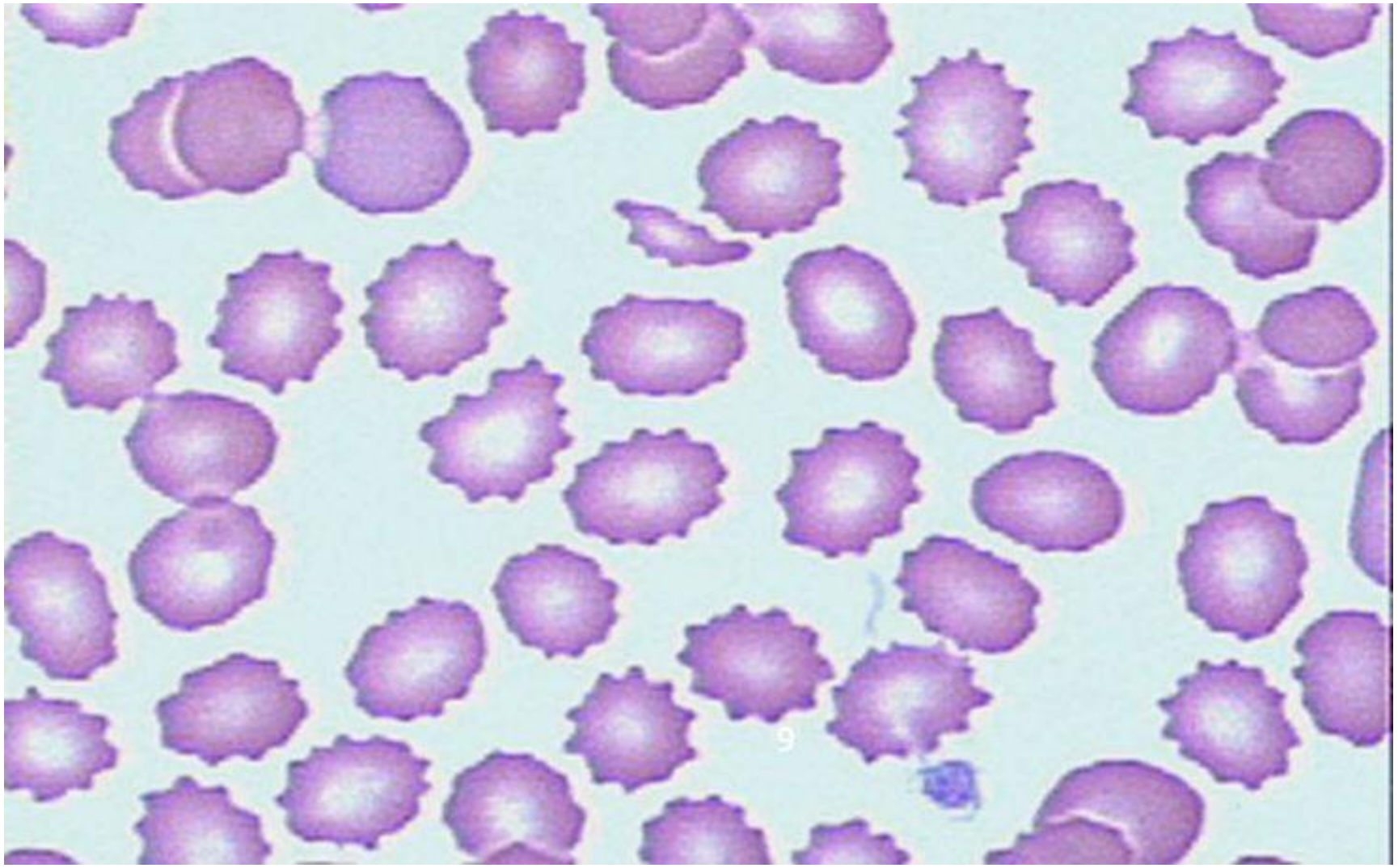

- Patients with anemia of kidney disease who are not yet on hemodialysis with a hg level > 10 g/dl should not receive erythropoitic stimulating agents(ESA). Those with a hg < 10, should receive individualized ESA therapy based on symptoms , rapidity of anemia and transfusion needs.
- patients on hemodialysis , with a hg level < 10 , should receive ESAs . However , hg level should not exceed 11.5 g/dl (risk of HTN, volume overload and thrombotic events) .

Cobalamin deficiency

- Cobalamin is essential in DNA synthesis
- Its deficiency will result in megaloblastic anemia , ineffective hematopoiesis and as a result intramedullary hemolysis and pancytopenia .
- causes of vitamin b12 deficiency :

- Diet : rare cause , only in strict vigans.
- Malabsorption :most common cause; IBD, bacterial overgrowth , pancreatic insufficiency
- Decreased bioavailability : age related gastric achlorhydria , PPI use
- Pernicious anemia : autoimmune antibodies against parietal cells or the intrinsic factor.

- Presentation :

- weight loss , glossitis, anemia symptoms , lemon-yellow skin (anemia and jaundice secondary to hemolysis caused by ineffective erythropoiesis).
- Severe deficiency can cause neurological manifestations(subacute combined degeneration of the spinal cord) even before anemia. Loss of vibration and proprioception , spastic ataxia , psychiatric symptoms (megaloblastic mania) which manifest as dementia , hallucinations and even frank psychosis.

- Blood film : oval macrocytes with hypersegmented neutrophils , pancytopenia .
- Ineffective hematopoiesis and resulting intramedullary hemolysis : indirect hyperbilirubinemia , decreased haptoglobin and elevated LDH levels.
- Low reticulocyte count
- Low serum vitamin b12 , < 200
- Sometimes low normal levels don’t indicate the level of tissue vitamin b12 , so to confirm diagnosis : elevated MMA (methylmalonic acid) , more sensitive , also elevated homocysteine levels. (in folate deficiency MMA is normal , homocysteine is elevated).

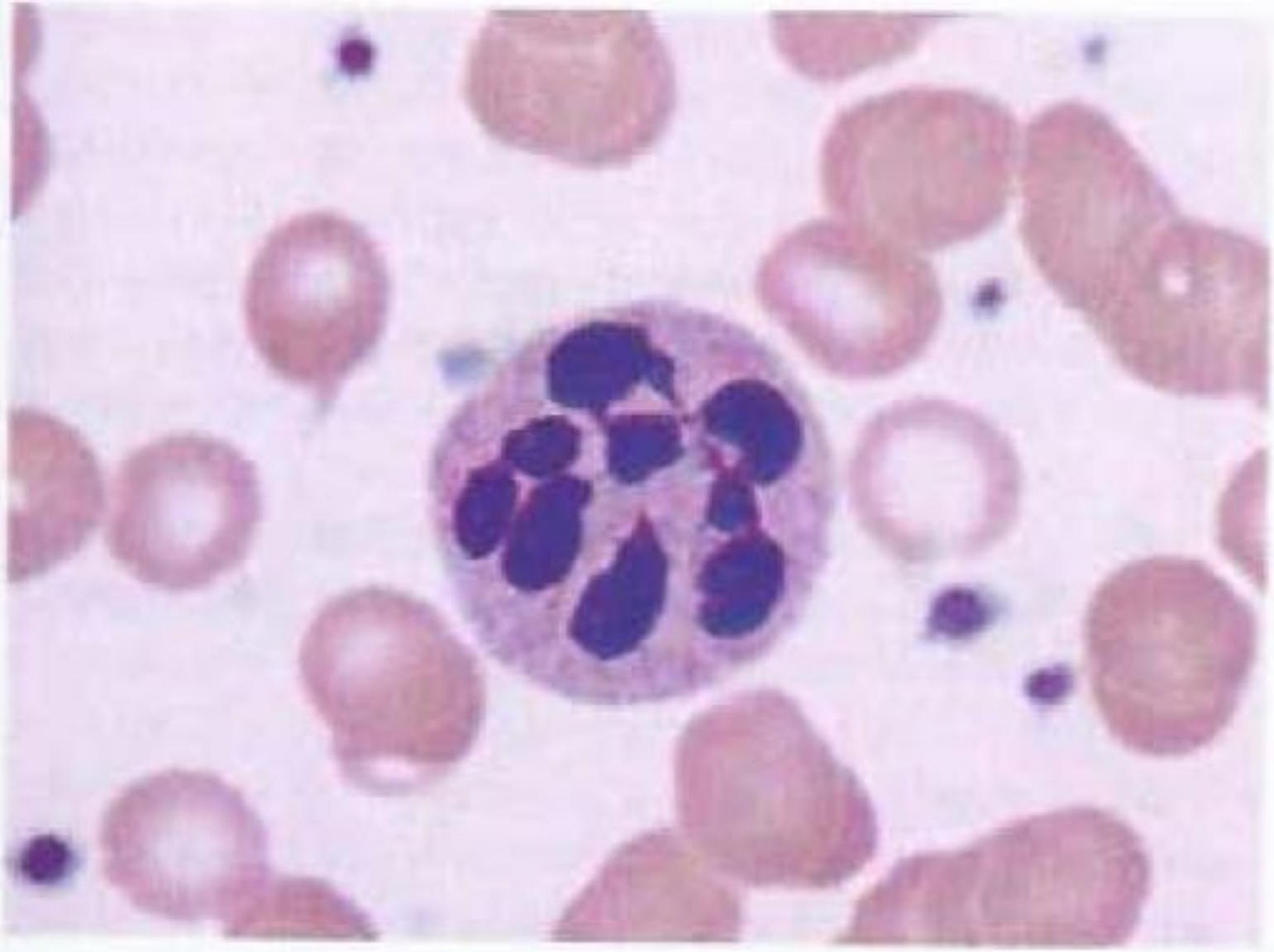

FIGURE 10. Hypersegmented polymorphonuclear (PMN) cell in a patient with pernicious anemia. The presence of hypersegmented PMNs becomes significant when they constitute greater than 5% of PMNs with five or more lobes or 1% with six or more lobes.

- **oral** cobalamin 1000-2000 micrograms daily is the treatment of choice (even in pernicious anemia and malabsorption !)
- Megaloblastic changes will be reversed within hours , reticulocytosis within days , hg level will increase 1 g/week .
- Neuropsychiatric symptoms may not be reversed with replacement !
- Inadequate response : consider another diagnosis like myelodysplasia.

Folate dificiency

- Causes :

- Malnutrition
- Malabsorption : alcohol intake, IBD , celiac disease, amyeloidosis
- Increased demand : conditions with rapid cell turnover (pregnancy , psoriasis , hemolysis)
- Drugs : causes decreased absorption or inhibit converting to active form ; phenytoin , methotrexate , triamterene.

- Presentation is similar to vitamin b12 deficiency (except neuropsychiatric symptoms)
- Diagnosis : low serum folate , if normal cant be reliable , so elevated homocysteine level in suspected folate deficiency confirms the diagnosis .
- Management : oral folic acid 1-5 mg daily after exclusion of vitamin b12 deficiency.

Thalassemia

- It’s a disorder of erythrocyte production
- Ineffective erythropoiesis (erythrocyte underproduction)
- Hemoglobin is a tetramer of 2 beta chains and 2 alpha chains which are produced in a balanced way.
- Genes responsible for alpha and beta chains production are located on chromosomes 16, 11 respectively.
- Imbalanced production results in impaired production of hemoglobin and ineffective erythropoiesis .

- Peripheral blood smear: microcytic hypochromic anemia , target cells , nucleated RBCs .
- Unlike IDA; heterozygous thalassemia causes hypochromic microcytic anemia with normal to elevated RBC count and normal RDW.
- Increased LDH , indirect hyperbilirubinemia , low haptoglobin level.

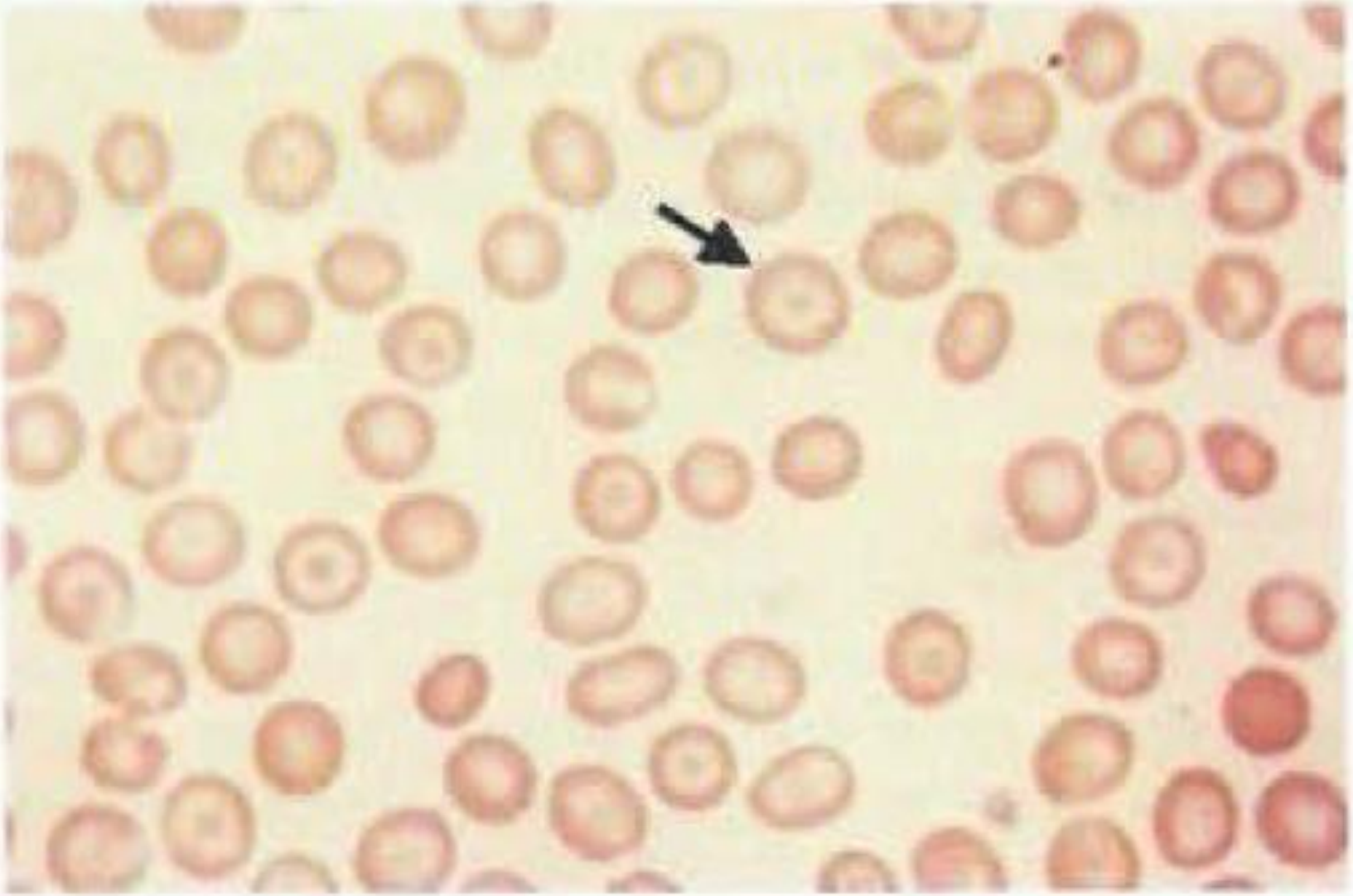

FIGURE 11. This peripheral blood smear in a patient with β-thalassemia major shows target cells (erythrocytes with an area of central density surrounded by pallor and then a rim of density) and a prominent nucleated erythrocyte.

- **<u>Alpha thalassemia</u>**

- Alpha globulin gene is duplicated on chromosome 16 >> several genotypes.
- Homozygous alpha thalassemia : hydrops fetalis
- A single gene mutation : silent carriers , healthy
- Two gene mutations : alpha thalassemia trait

- hg level around 10 g/dl , microcytosis , normal to elevated iron stores , normal hg electrophoresis , best diagnosed by direct sequencing of globin genes. Folate supplement

- Three gene mutations : tetramer of beta chains called hemoglobin H , can be identified in hg electrophoresis. more severe anemia , hg around 7-8 g/dl , seldom transfusion-dependant.

- **Beta thalassemia** :

- More than 250 mutations have been identified in beta globin gene >> a spectrum of the disease.
- Beta thalassemia minor (trait): microcytosis , hg level 10-12 g/dl, abnormal hg electrophoresis (increased hgA2 (alpha 2:gamma2) , sometimes increased hgF depending on the specific mutation.
- Beta thalassemia intermedia : hg 7 g/dl without need for transfusion.
- Beta thalassemia major :Homozygous beta thalassemia : severe symptomatic anemia diagnosed at early age. Transfusion dependant
- Folate supplement , avoid iron supplements

Hemolytic anemias

- Ineffective erythropoiesis
- Immune injury mediated by immunoglobulins or complement
- Physical destruction by fibrin , valves and other intracirculatory devices.
- Symptoms depend on the severity of anemia and how acute the hemolysis is .
- Pigmented gallstones (insoluble calcium bilirubinate) in chronic hemolytic anemias.
- Reticulocytosis (if stores are good), indirect hyperbilirubinemia , elevated LDH , elevated serum free hemoglobin, hemoglobinuria

- Congenital vs acquired
- Congenital : hemoglobinopathies (sickle cell disease), disorders of the erythrocyte membrane (hereditary spherocytosis, hereditary elliptocytosis , hereditary pyropoikilocytosis), enzyme defects (G6PD deficiency).
- Acquired : drugs (penicillin , quinine , fludarabine ,bendamustine , methyldopa), immune mediated , micro or macroangiopathies , infections and physical agents.

Congenital hemolytic anemias

Hereditary spherocytosis

- AD disorder
- Many gene mutations have been identified : alpha spectrin, beta spectrin , ankyrin , band 3 , protein 4.2
- Osmotic fragility , reduced surface area to volume ratio , splenic sequestration
- Symptoms are variable : mild unrecognized anemia , symptomatic anemia(acute BM suppression after viral infection) , splenomegaly (rarely splenic infarction or rupture), calcium bilirubinate pigmented gallstones.

- Peripheral smear : spherocytes
- Variable degrees of anemia ,hyperbilirubinemia , reticulocytosis , high MCHC.
- Diagnosis : osmotic fragility test , flowcytometry

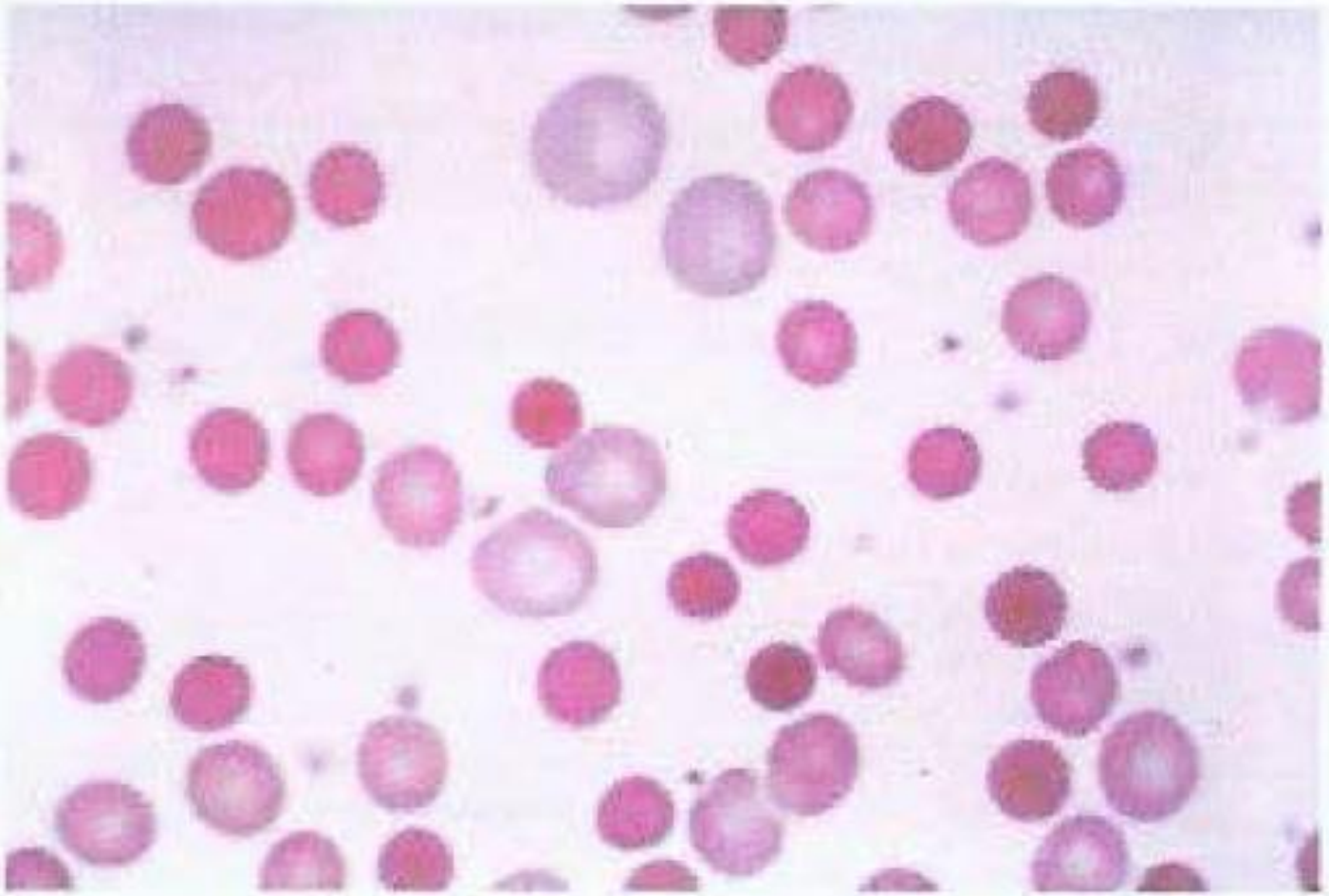

FIGURE 12. This peripheral blood smear in a patient with hereditary spherocytosis shows round cells of uniform density (without central pallor) characteristic of spherocytes.

- Folate supplement
- Splenectomy in severe hemolysis

G6PD deficiency

- X-linked disease
- More than 160 mutations
- Two variants (G6PD A : mild form , G6PD Mediterranean (favism))
- Partial protection against malaria infection
- G6PD is essential in pentose-phosphate pathway , reduction NADP to NADPH >> reduce oxidative stress)
- Triggers of hemolysis : drugs , fava beans , naphthalene

- Peripheral smear : bite cells , Heinz bodies (denatured hemoglobin)on supravital stain.
- Diagnosis : fluorescent spot test to detect NADPH (+ve : lack of fluorescence, not in acute hemolysis) ; qualitative G6PD enzyme activity and subtyping (more specific)

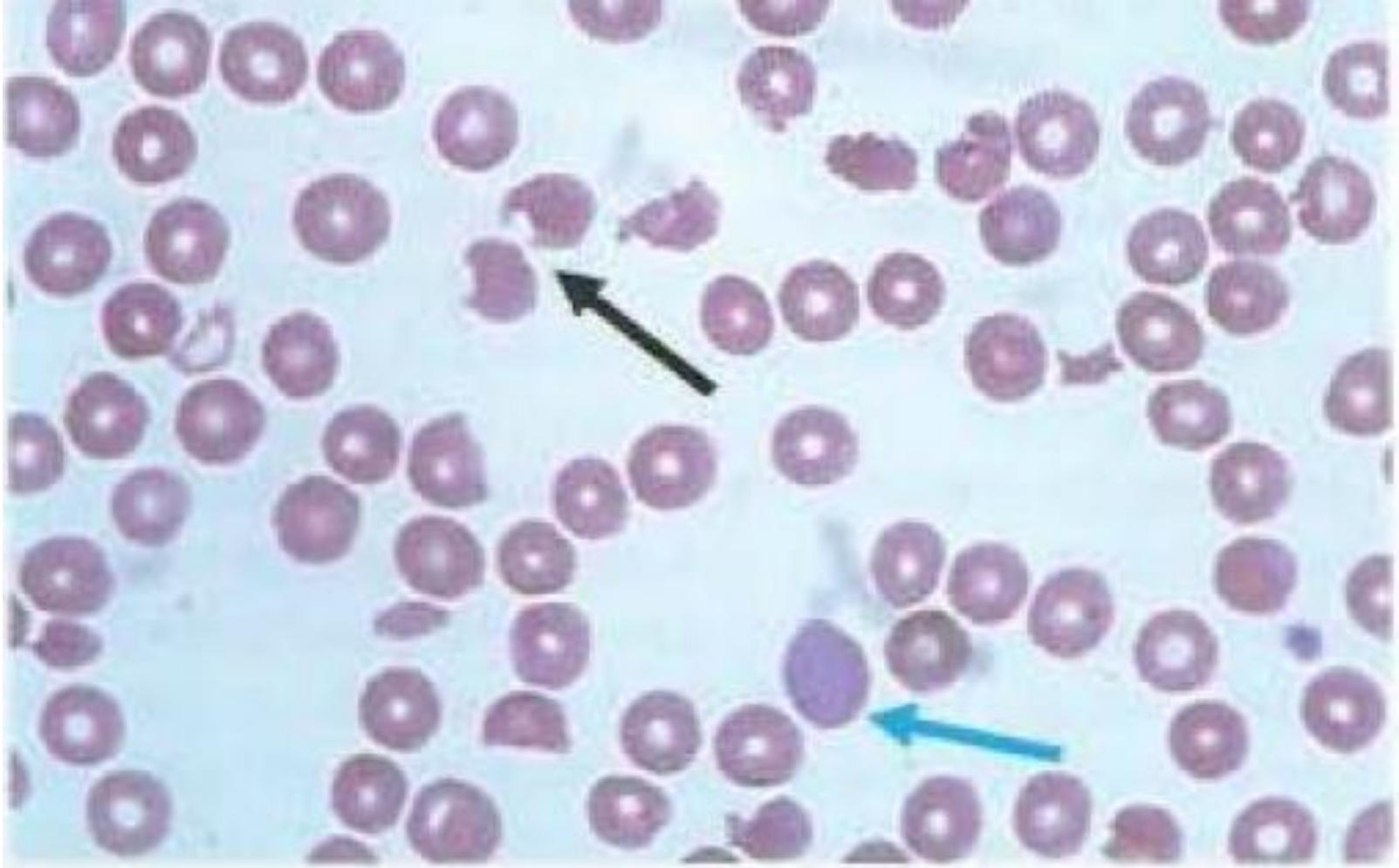

FIGURE 13. Bite cells seen at the center of this slide are typical findings in glucose-6-phosphate dehydrogenase deficiency and are characterized by a membrane defect that appears as though a semicircular bite has been taken out of the erythrocyte. The defect is caused by removal of denatured hemoglobin by macrophages in the spleen. A polychromatophilic macro-ovalocyte can also be seen (bottom), indicating a reticulocyte response.

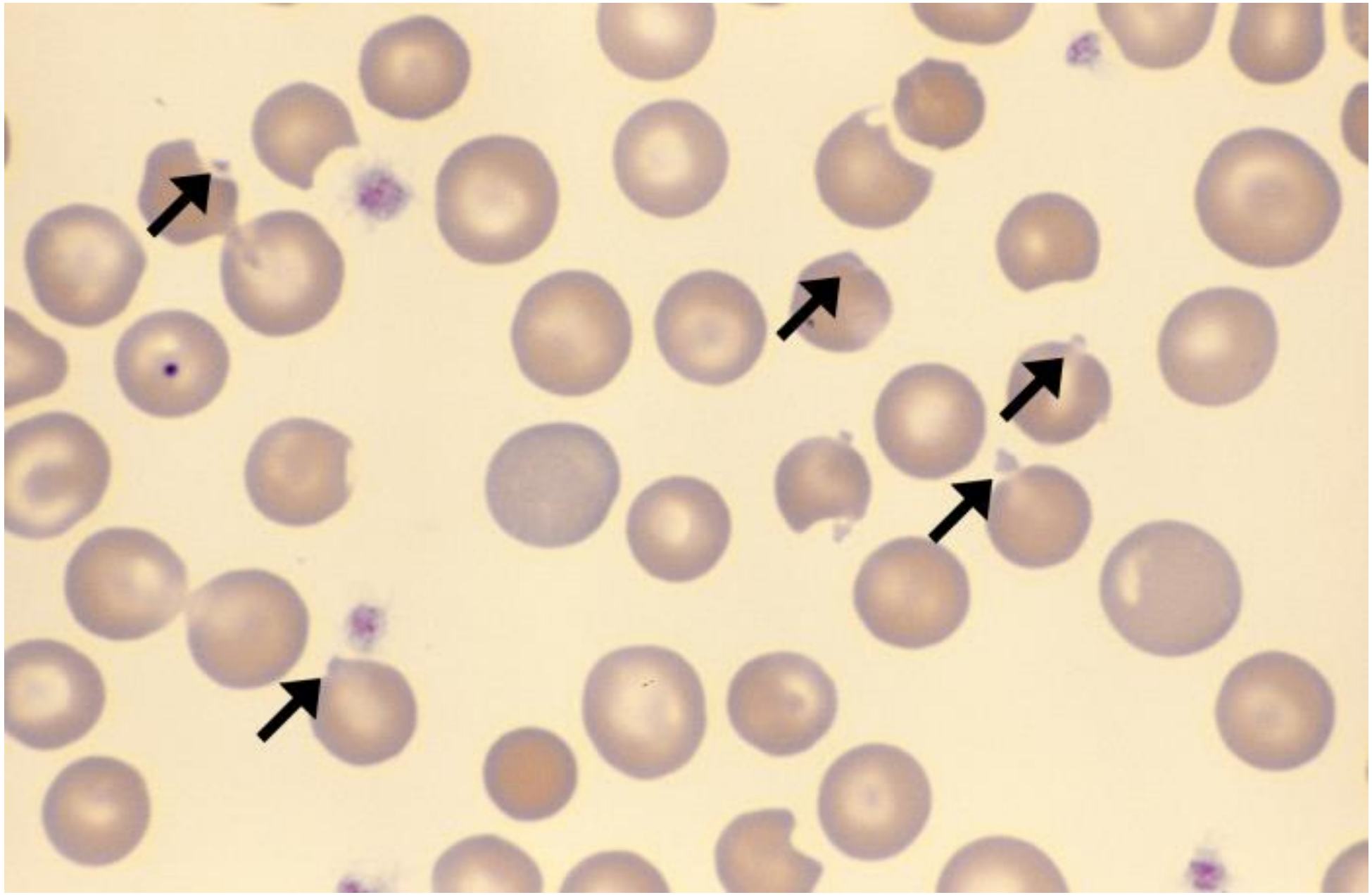

Sickle cell syndromes

- Homozygosity of a single point mutation in the 6th position of the beta globin gene >> abnormal hemoglobin S (Hb S) >> polymerizes under hypoxic conditions >> deformed erythrocytes that adhere to the endothelium of capillaries throughout the circulation.
- Hemolyzed erythrocytes release arginase , depleting the body from arginine which is an important precursor of nitric oxide
- Free hemoglobin scavenges nitric oxide
- This will lead to vasoconstriction and platelet activation which will lead to a more complicated clinical course .

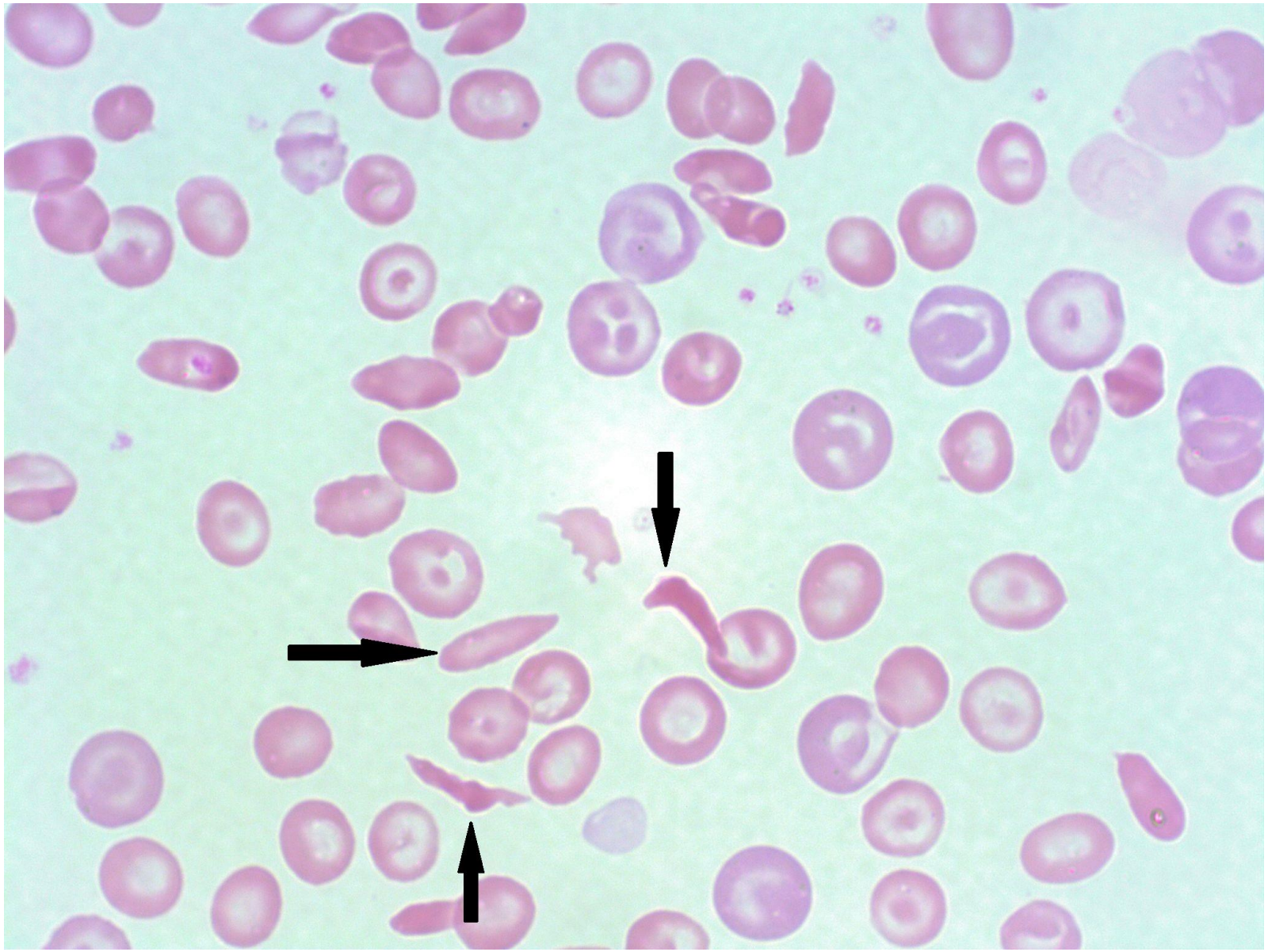

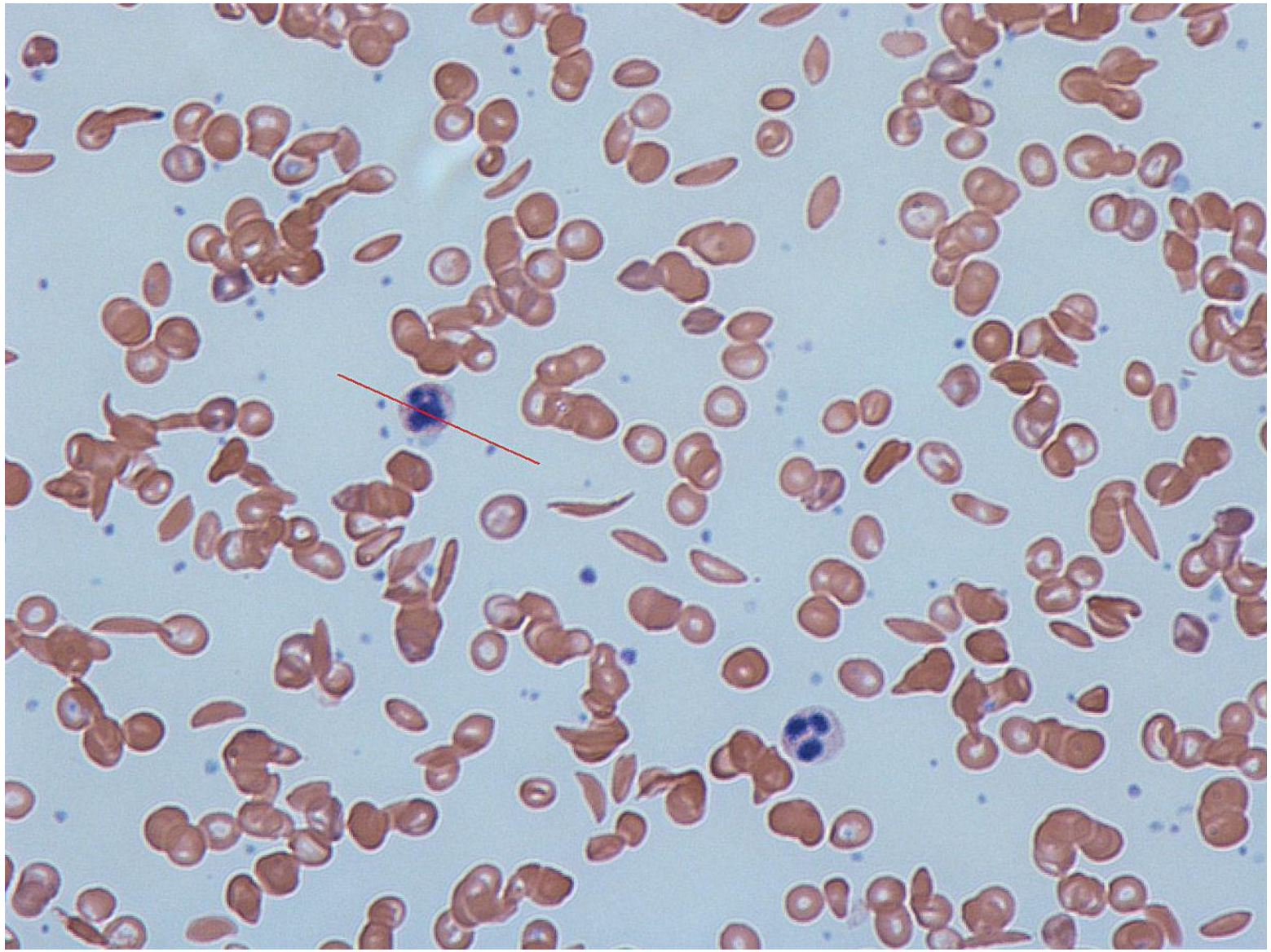

- Homozygous (Hb SS) : having the disease , most severe
- Sickle cell trait (Hb S)
- Coinheritance with Hb C (Hb SC) , B-thalassemia (S B thalassemia) and other hemoglobins which usually lead to milder disease than Hb SS.

TABLE 15. Characteristics of Adult Sickle Cell Syndromes

Disease Type	Hb (g/dL [g/L])	MCV (fL)	Hb S (%)	Hb A (%)	Hb A_2 (%)	Peripheral Blood Smear Findings	Clinical Severity[a] 0 to +++
Sickle trait (AS)	NL	NL	40	60	<3.5	NL	0
Hb SS	6-8 (60-80)	NL	>90	0	<3.5	Sickle cells	+++
$S\beta^+$-thalassemia	9-12 (90-120)	70-75	>60	10-30	>3.5	Rare sickle cells Target cells	+ to ++
$S\beta^0$-thalassemia	7-9 (70-90)	65-70	>80	0	>3.5	Sickle cells Target cells	+++
SCD	10-15 (100-150)	75-NL	50	0	Hb A_2 = 0 Hb C = 50[b]	Sickle cells Target cells	+ to ++

Hb = hemoglobin; Hb SS = homozygous sickle cell anemia; MCV = mean corpuscular volume; NL = normal; $S\beta^+$ = sickle β^+; $S\beta^0$ = sickle β^0; SCD = hemoglobin SC disease.

[a]Clinical severity is variable within each genotype.

[b]Note that Hb C comigrates with Hb A_2 on standard alkaline cellulose acetate electrophoresis but will separate on citrate agar electrophoresis.

NOTE: Hb percentages may not total 100% because Hb F is not included in this table.

TABLE 16. Common Complications and Treatments in Adults with Sickle Cell Disease

Complications	Treatment
Vaso-occlusive pain episode	**Acute:** rest, relaxation, warmth, NSAIDs, oral and IV hydration, narcotic analgesia
	Recurring: HU for more than 3 episodes/year, pain that interferes with daily activities; avoidance of triggers; nonnarcotic or narcotic analgesia
Acute chest syndrome	**Acute:** oxygen, incentive spirometry, analgesics, empiric antibiotics, IV fluids, simple or erythrocyte exchange transfusions
	Preventive: HU for recurrent acute chest syndrome, incentive spirometry in hospitalized patients
Aplastic crisis	**Acute:** supportive care, blood transfusions as needed
Infection	**Acute:** appropriate and immediate antibiotic management (particular concern for encapsulated bacteria)
	Prevention: influenza, pneumococcal, and meningococcal vaccines
Hyperhemolytic crisis	**Acute:** supportive care, avoid further blood transfusions, immunosuppression might be helpful
	Preventive: avoid blood transfusions if possible, extended antibody screen can lessen but not eliminate recurrence

Multiorgan failure	**Acute:** erythrocyte exchange transfusions
Ischemic stroke	**Acute:** erythrocyte exchange transfusions, aspirin
	Preventive: chronic simple transfusions or erythrocyte exchange transfusions (target Hb S <30%-50%)
Hepatic crisis	**Acute:** supportive, transfusion or exchange transfusion if anemia is symptomatic
Cholelithiasis	**Acute:** if symptomatic, cholecystectomy with preoperative transfusions to hemoglobin of 10 g/dL (100 g/L)
Chronic kidney disease/ proteinuria	**Preventive:** blood pressure control to <130/80 mm Hg
	Secondary preventive: ACE inhibitor or ARB in patients with microalbuminuria
Priapism	**Acute:** relaxation, hydration, narcotic analgesics, aspiration of blood from corpora cavernosa and irrigation with dilute epinephrine, transfusions, shunt procedure
	Preventive: oral α-adrenergic agonists, HU. The role of leuprolide and sildenafil is not clear.
Pulmonary hypertension	No proven therapy established for prevention or treatment
Retinopathy	Annual ophthalmologic examination, laser phototherapy for retinopathy
Osteopenia/osteoporosis	Supplementation with calcium and vitamin D, bone mineral density measurements
Avascular necrosis	Analgesics and physical therapy, arthroplasty
Foot and leg ulcers	**Acute:** early aggressive treatment, debridement, bandage impregnated with zinc oxide
	Preventive: proper footwear to prevent pressure points

ARB = angiotensin receptor blocker; Hb S = hemoglobin S; HU = hydroxyurea; IV = intravenous.

TABLE 17. Strong Recommendations from the National Institutes of Health/U.S. Department of Health and Human Services Guidelines for the Management of Sickle Cell Disease
Rapid initiation of opioids for vaso-occlusive crisis
Use of incentive spirometry in hospitalized patients
Use of analgesics and physical therapy for treatment of avascular necrosis
Use of ACE inhibitors in patients with microalbuminuria
Regular ophthalmologic examinations and referral for laser photocoagulation for retinopathy
Use of echocardiography to evaluate signs of pulmonary hypertension
Hydroxyurea for patients with more than 3 vaso-occlusive crises per year, for those with pain or chronic anemia interfering with daily activities, or those with recurrent acute chest syndrome
Preoperative transfusion to serum hemoglobin level of 10 g/dL (100 g/L) for surgeries requiring general anesthesia
Assess for iron overload and begin oral iron chelation if necessary

- The only potential cure : allogenic bone marrow transplantation (not studied well)
- Hydroxyurea (increases fetal hemoglobin level , increases nitric oxide production.). Reduces subsequent acute pain crisis, reduces the risk of stroke and acute chest syndrome , prolongs survival .
- Painful crises : oral glutamine (NAD precursor), P selectin inhibitor crizanlizumab (prevent cellular adhesion)

Acquired hemolytic anemia

Immune – mediated hemolysis :

- Antibody binds to erythrocyte >> complement and phagocyte mediated RBC destruction
- The lab hallmark : +ve direct comb’s test
- Warm antibodies (igG , reacts at body temp.) vs cold antibodies (IgM , react at cooler temp.)

- Warm autoimmune hemolytic anemia

- Primary vs secondary to drugs (penicillin , methyldopa), lymphoproliferative disorders (CLL), diseases with disordered immune regulation (SLE)
- Spherocytes on blood film
- Management : steroids , IVIG , rituximab , splenectomy (effective in 70% of patients)

- Cold agglutinin disease :

- Blood film : erythrocyte agglutination , markedly elevated MCV
- Causes : lymphoproliferative disorders , infections (mycoplasma , EBV infection)
- Management : avoidance of cold exposure (mainstay of tt)
- Steroids , IVIG, and splenectomy are seldom effective
- Rituximab , fludarabine or combination has demonstrated activity in some case series.

TABLE 18. Characteristics of Warm Autoimmune Hemolytic Anemia (WAIHA) and Cold Agglutinin Disease

Characteristic	WAIHA	Cold Agglutinin Disease
Temperature for optimal antibody binding to erythrocytes	37.0 °C (98.6 °F)	<37.0 °C (98.6 °F)
Immunoglobulin class	IgG	IgM
Typical AGT pattern	IgG positive, C3 positive or negative	IgG negative, C3 positive
Peripheral blood smear findings	Spherocytes	Erythrocyte agglutination
Clinical manifestations[a]	Anemia, fatigue, dyspnea, jaundice, splenomegaly	Anemia, fatigue, dyspnea, jaundice, acrocyanosis, splenomegaly
Associated conditions	Autoimmune, lymphoproliferative (chronic lymphocytic leukemia, B-cell non-Hodgkin lymphomas), drug-induced[b]	Infectious (*Mycoplasma* and Epstein-Barr virus), lymphoproliferative (IgM MGUS, Waldenström macroglobulinemia, other B-cell non-Hodgkin lymphomas)
Treatment	Glucocorticoids, splenectomy, immunosuppression, treatment of underlying condition	Cold avoidance, rituximab, plasmapheresis, treatment of underlying condition

AGT = antiglobulin (Coombs) test; MGUS = monoclonal gammopathy of undetermined significance.

[a]Manifestations in cold agglutinin disease are worse upon exposure to the cold. Lymphadenopathy in either entity should raise suspicion of a lymphoproliferative disorder.

[b]Cephalosporins, penicillins, NSAIDs, isoniazid, procainamide, methyldopa, levodopa.

Nonimmune hemolytic anemia

- Microangiopathic hemolytic anemia :

- Blood film : fragmented RBCs (shistocytes)
- Erythrocyte destruction resulting from shearing as they circulate through fibrin strands.
- TTP , HUS , malignancy , DIC , hypertensive crisis , drugs (cyclosporine , mitomycin , gemcitabine), eclampsia
- Often accompanied by thrombocytopenia , kidney impairment , CNS disturbance.

FIGURE 15. Peripheral blood smear showing schistocytes, or fragmented erythrocytes.

- Macroangiopathic hemolytic anemia
- Prosthetic valves
- LVAD (left ventricular assist device)

- Paroxysmal nocturnal hemoglobinuria (PNH)

- Lack proteins on the erythrocyte surface
- Acquired mutations in the PIGA gene that persists in bone marrow stem cells.
- CD55 , CD59 protects erythrocytes from complement mediated destruction.
- Presentation : episodic hemolysis , marrow aplasia and thrombosis (unclear etiology) .
- Higher risk for leukemia and myelodysplasia
- Diagnosis : flowcytometry (absence of cd55 cd59)

- Management : folate supplementation , steroids , eculizumab (a novel monoclonal antibody to C5 , inhibition of terminal complement cascade thus inhibits hemolysis , reduces thrombotic complications and improve quality of life , meningococcal vaccine before use)

- Hemolysis associated with chemical and physical agents :

- Arsenic , elevated serum copper , bite of brown recluse spider , severe burns

- Hemolysis from infections :

- Malaria , babesiosis , clostridia , bartonella