Inflammatory Bowel Disease (IBD)

Dr. Mu’taz M Massad
Assistant Professor
Faculty of medicine- Hashemite University.

- Ulcerative colitis
- Crohn disease.

- Undetermined colitis

Epidemilogy

- UC : incidence 2-14 cases / 100,000 person-year. Prevalence 238/100,000.
- CD: incidence 3-20 cases / 100,000 person-year. Prevalence 201/100,000.

- **Bimodal age** onset for many patients with ulcerative colitis and Crohn disease is between 15 and 30 years with a possible second peak between 50 and 80 years of age.

- **Sex** – Small differences in IBD incidence by sex have been reported. There is a slight female predominance in adult-onset Crohn disease, which suggests that hormonal factors may play a role in disease expression. In contrast, there may be a slight male predominance in ulcerative colitis . In a study using data from the Rochester Epidemiology Project, male sex was associated with a higher incidence rate of ulcerative colitis compared with female sex (12.8 versus 8.8 cases per 100,000 person-years)

- **Race and ethnicity** – Both ulcerative colitis and Crohn disease are more common in Jewish compared with non-Jewish populations.

- **Physical activity** — Physical activity has been associated with a decrease in risk of Crohn disease, but not ulcerative colitis.

CLINICAL RISK FACTORS
Lifestyle factors

- **Smoking** :
- Smoking is a risk factor for Crohn's disease but not for ulcerative colitis.
- Smoking also increases the risk complications from Crohn disease (eg, strictures, fistula) and the need for surgery.

- Current smoking is not a risk factor for and may lower the risk of developing ulcerative colitis
- Smoking cessation in patients with ulcerative colitis is associated with an increase in disease activity and risk of hospitalization.

Ulcerative colitis

- Chronic inflammatory condition characterized by relapsing and remitting episodes of inflammation limited to the mucosal layer of the colon. It almost invariably involves the rectum, and the extent often involves more proximal portions of the colon in a continuous fashion.

- Usually pts presenting with : diarrhea (+/- bloody), urgency, tenesmus, abd. Pain or fever.

Proctitis
Affected Regions

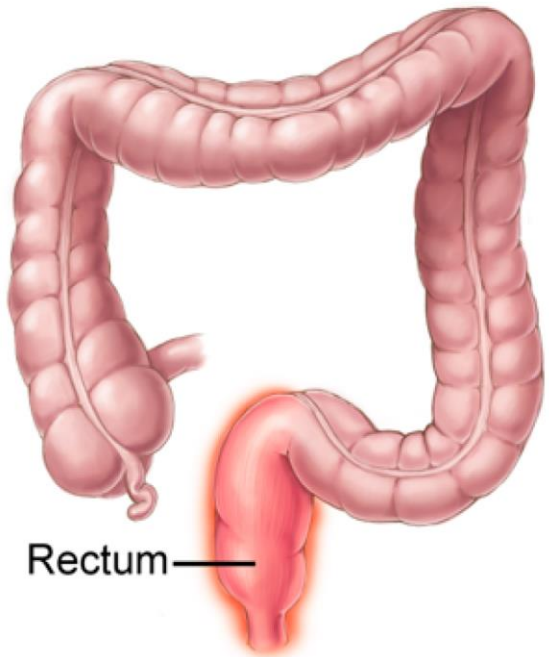

Left-sided Colitis
Affected Regions

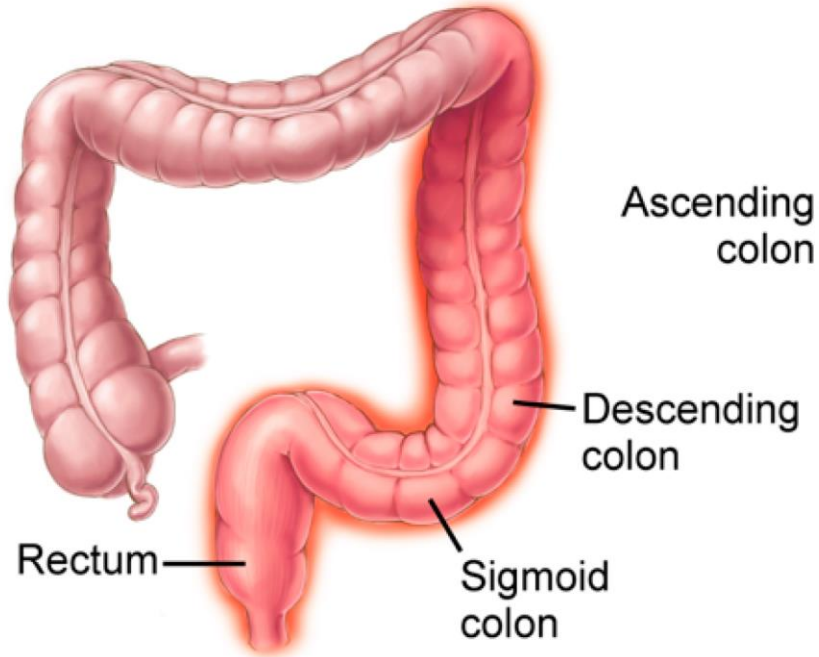

Extensive (Pan) Colitis
Affected Regions

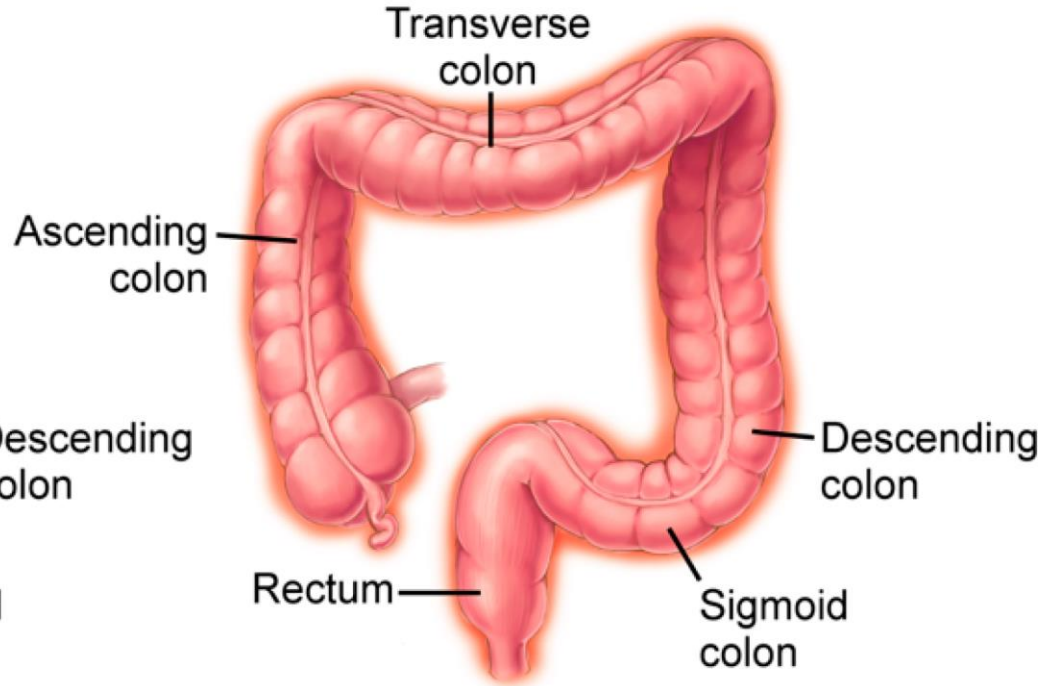

J Gregory ©2019 Mount Sinai Health System

- Affect the colon .
- onset of symptoms is usually gradual, and symptoms are progressive over several weeks.
- The severity of symptoms may range from mild disease with four or fewer stools per day with or without blood to severe disease with more than 10 stools per day with severe cramps and continuous bleeding.
- Patients may have systemic symptoms including fever, fatigue, and weight loss. Patients may also have dyspnea and palpitations due to anemia secondary to iron deficiency from blood loss, anemia of chronic disease, or autoimmune hemolytic anemia.

Clinical parameters	Disease severity			
	Mild	Moderate	Severe	Fulminant
Stool variables				
Number per day	<4	≥4	>6	>10
Stool appearance	±blood	±blood	+blood	Continuous rectal bleeding
Clinical features				
Temperature (°C)	Normal	Normal or >37.5	>37.5	>37.5
Heart rate	Normal	Normal or tachycardic	Tachycardic	Tachycardic
Clinical signs	No signs of toxicity	Minimal signs of toxicity	Increasing signs of toxicity; abdominal pain	Toxic-appearing; abdominal pain/distension
Objective data				
Erythrocyte sedimentation rate (mm/hour)	≤30 (normal)	Normal or elevated	>30 (elevated)	>30 (elevated)
Hemoglobin	Normal	Normal or low	Anemia (<75% of normal value)	Anemia requiring transfusion
Radiographic imaging			Colonic air and bowel wall edema with thumbprinting	Colonic dilation

Acute complications

- **Severe bleeding**
- **Fulminant colitis and toxic megacolon** > 10 stools per day, continuous bleeding, abdominal pain, distension, and acute, severe toxic symptoms including fever and anorexia.
  Patients with fulminant colitis are at higher risk of developing toxic megacolon as the inflammatory process extends beyond the mucosa to involve the muscle layers of the colon.
- Toxic megacolon is characterized by colonic diameter ≥6 cm or cecal diameter >9 cm and the presence of systemic toxicity.
- **Perforation**

Extraintestinal manifestations (EIM)

- **Musculoskeletal:** Arthritis is the most frequent EIM of IBD.
  -nondestructive peripheral arthritis, (large joints) and ankylosing spondylitis.
  -osteoporosis, osteopenia, and osteonecrosis.
- **Eye:** most frequent ocular manifestations of IBD include uveitis and episcleritis . Scleritis, iritis, and conjunctivitis have also been associated with IBD
- **Skin:** The most frequent skin lesions associated with IBD include erythema nodosum and pyoderma gangrenosum
- **Hepatobiliary:** Primary sclerosing cholangitis, fatty liver, and autoimmune liver disease.

- **Hematopoietic/coagulation** : increased risk for both venous and arterial thromboembolism, Autoimmune hemolytic anemia .
- **Pulmonary:** rare, include airway inflammation, parenchymal lung disease, serositis, and thromboembolic disease.

Anterior uveitis in a patient with inflammatory bowel disease

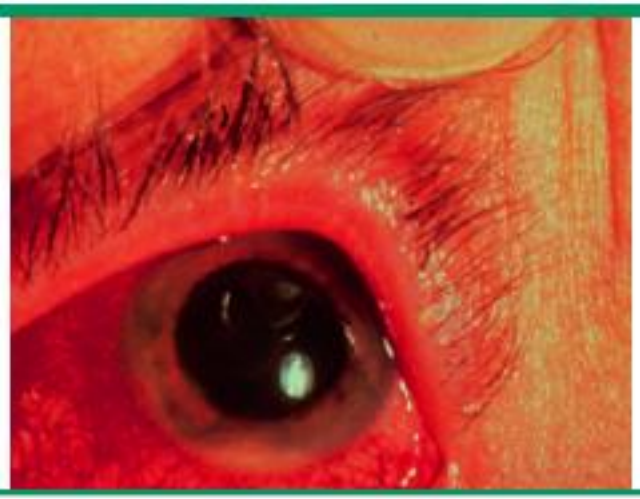

Anterior uveitis in a patient with inflammatory bowel disease is characterized by injection of the conjunctiva and opacity in the anterior chamber.

Courtesy of the American Gastroenterological Association©. This slide cannot be downloaded but may be purchased as part of a set from the AGA.

UpToDate®

Copyrights apply

Diffuse episcleritis

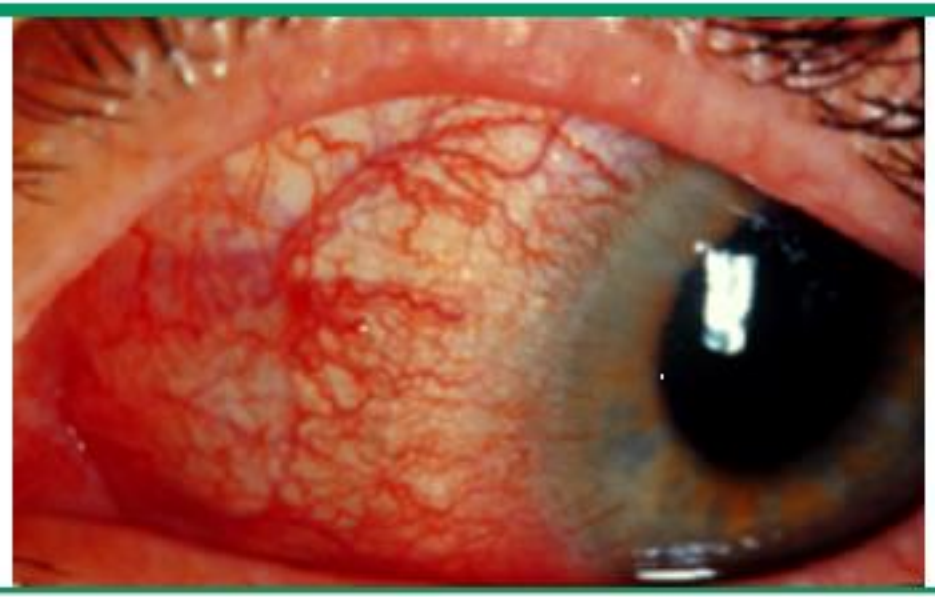

Monocular attack of diffuse episcleritis in a patient with relapsing polychondritis. There is diffuse injection of the episcleral vessels, but the underlying sclera is normal.

Courtesy of Reza Dana, MD, MSc, MPH.

UpToDate®

Copyrights apply

Erythema nodosum

Patient with inflammatory bowel disease with red nodular areas on the shins which are characteristic of erythema nodosum.

Courtesy of the American Gastroenterological Association©. This slide cannot be downloaded but may be purchased as part of a set from the AGA.

UpToDate®

Copyrights apply

Pyoderma gangrenosum

Early lesion in pyoderma gangrenosum presenting as a pustular and violaceous plaque with incipient breakdown.
Courtesy of Cynthia Magro, MD.

UpToDa

Pyoderma gangrenosum

Multiple active and healing lesions of pyoderma gangrenosum with cribriform scarring in patient with inflammatory bowel disease.

Courtesy of Samuel Moschella, MD.

UpToDate

Copyrights apply

LABORATORY FINDINGS

May have :

- anemia
- Elevated erythrocyte sedimentation rate (≥30 mm/hour)
- low albumin, and
- electrolyte abnormalities
- Elevation in serum alkaline phosphatase concentration
- Fecal calprotectin or lactoferrin may be elevated due to intestinal inflammation but are nonspecific

Imaging

- Abdominal imaging is not required for the diagnosis of ulcerative colitis but may be performed in patients who present with symptoms of colitis.

- Abdominal radiography is usually normal in patients with mild to moderate disease, but may identify proximal constipation, mucosal thickening or "thumbprinting" secondary to edema, and colonic dilation in patients with severe or fulminant ulcerative colitis.

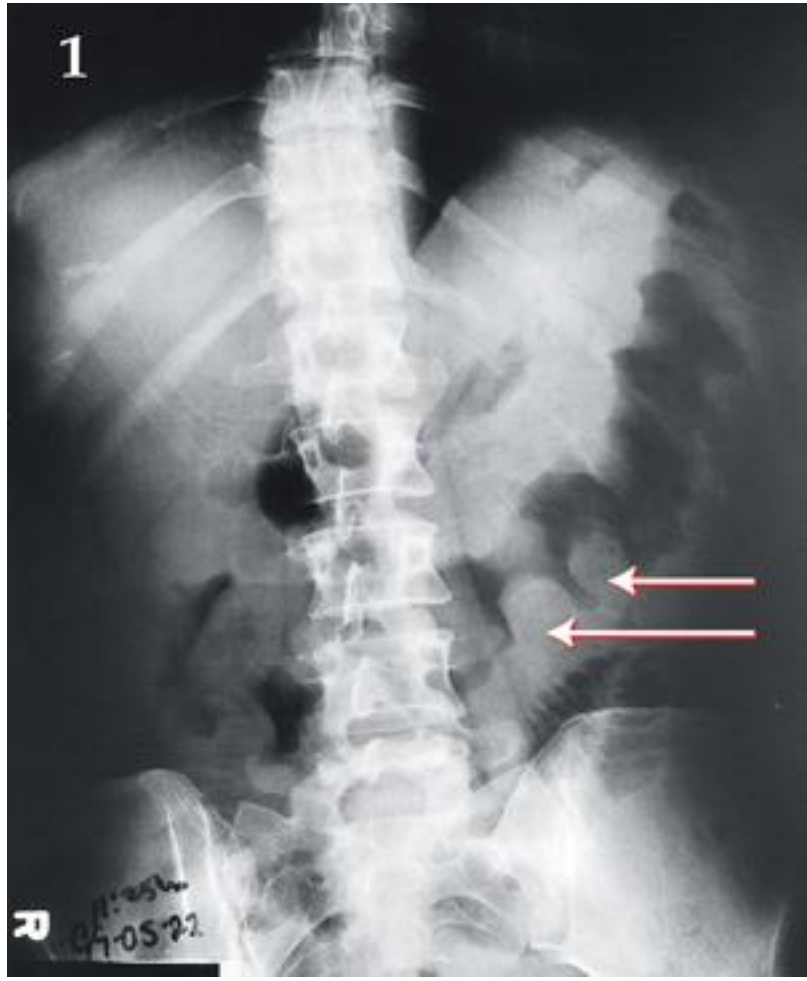

DIAGNOSIS

- Based on the presence of chronic diarrhea for more than four weeks and evidence of active inflammation on endoscopy and chronic changes on biopsy.(COLONOSCOPY WITH BIOPSIES) If fulminant colitis→ sigmoidoscopy

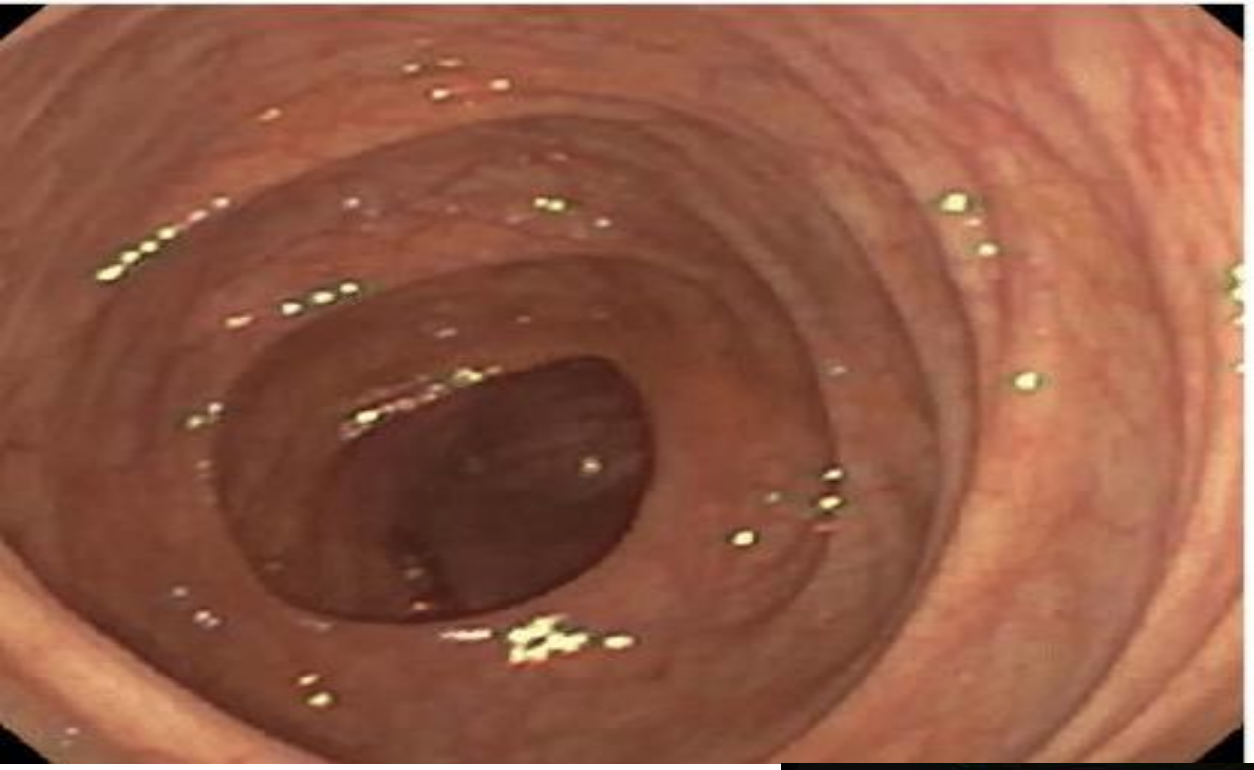

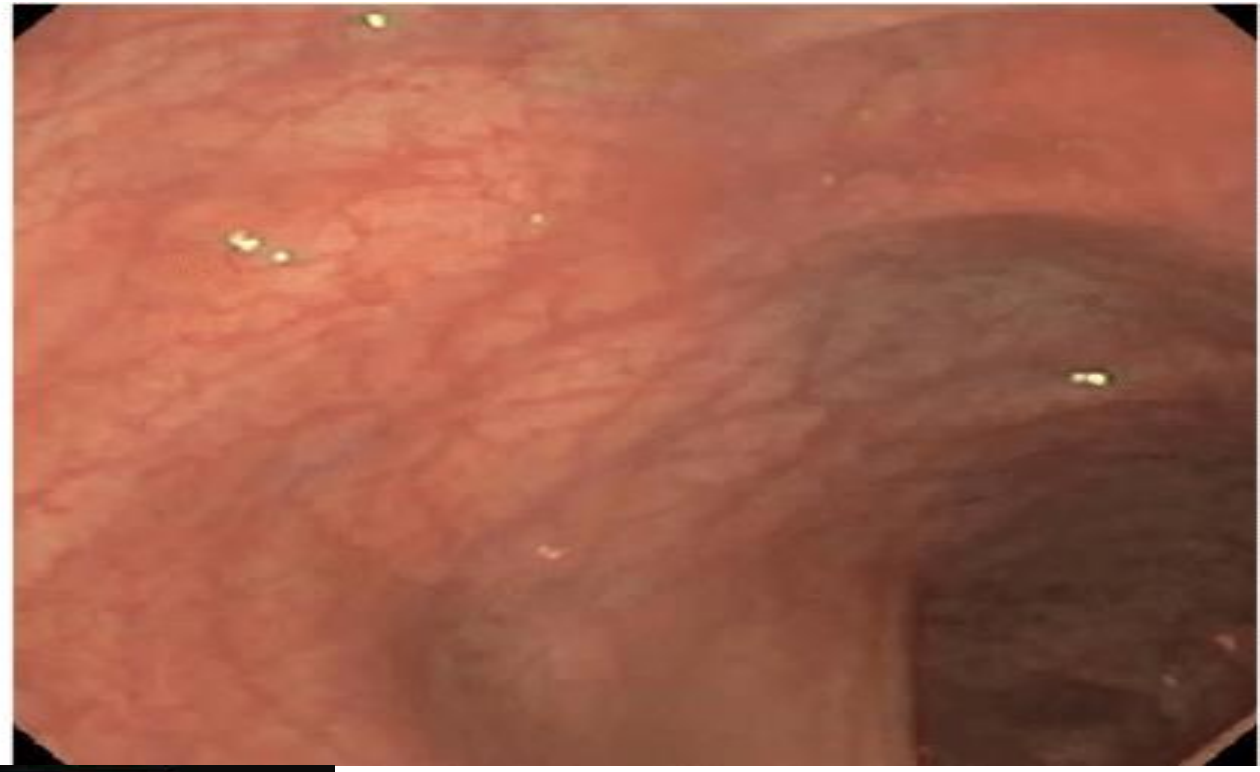

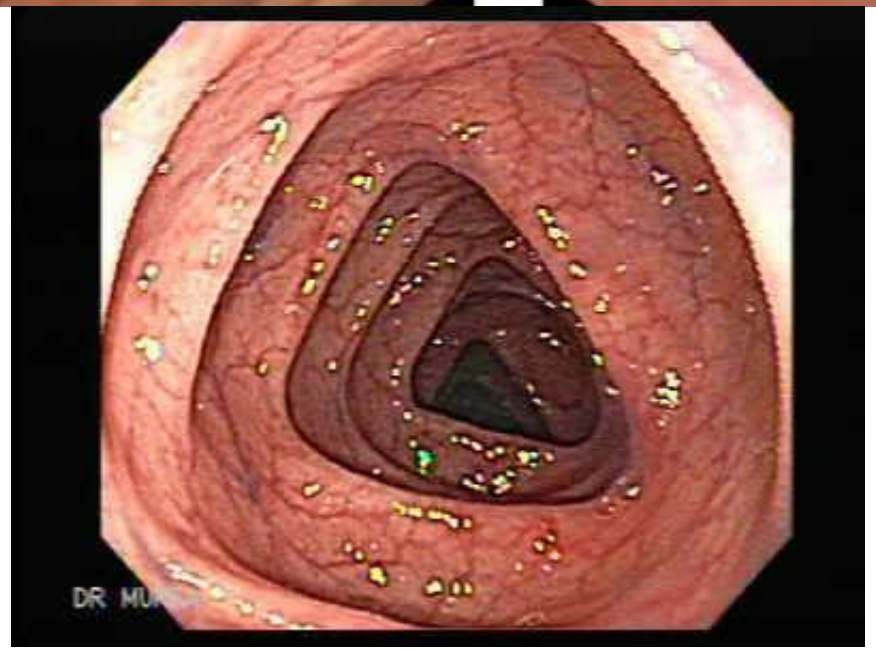
DR MU

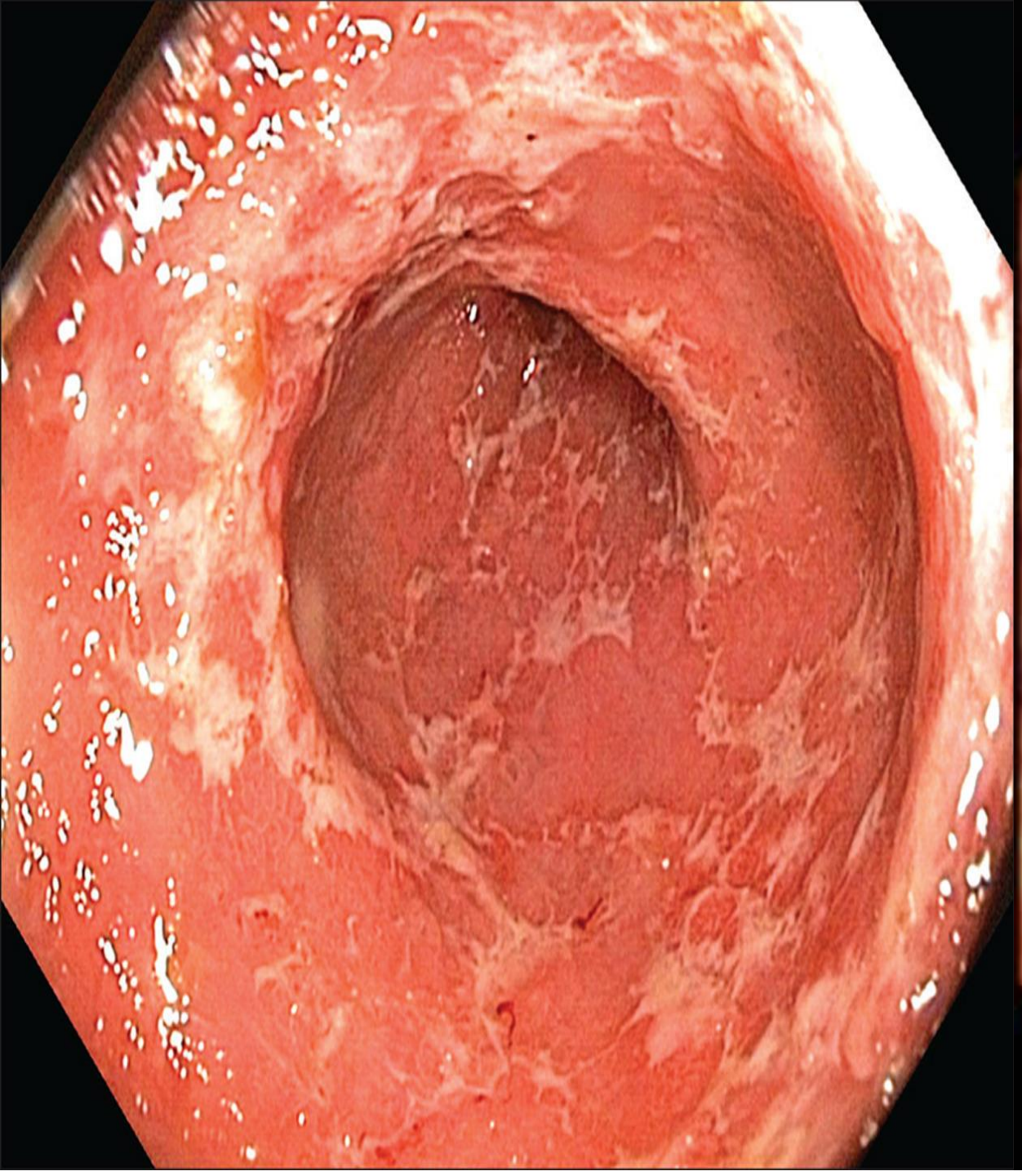

DIFFERENTIAL DIAGNOSIS

- **Crohn's disease**
- **Infection colitis**
- **Radiation colitis**
- **Diversion colitis** (in those with preceding colostomy)
- **Solitary rectal ulcer syndrome**
- **Diverticular colitis**
- **Medications induced colitis**
- **Graft versus host disease** (GVHD) in allogeneic transplant patients

Chronic Complications

Long term complications associated with UC include strictures, and the development of dysplasia and colorectal cancer (CRC) .

Surveillance colonoscopy ?

Treatment

- Depends on ?

- Proctitis :
- Proctosigmoiditis :
- Left sided colitis :
- Pancolitis :

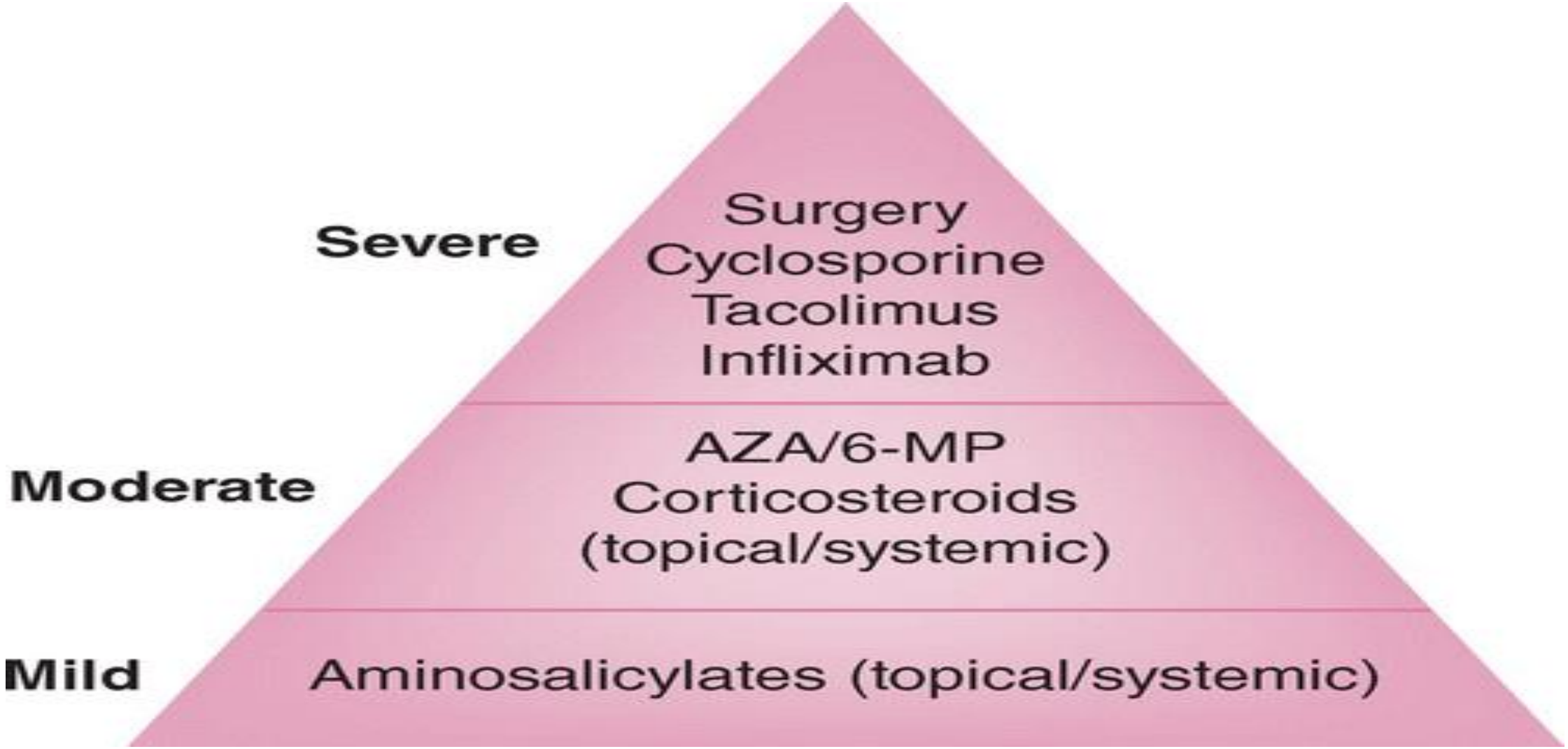
Severe
Surgery
Cyclosporine
Tacolimus
Infliximab
Moderate
AZA/6-MP
Corticosteroids
(topical/systemic)
Mild
Aminosalicylates (topical/systemic)

Crohn's disease

- Crohn's disease is characterized by transmural inflammation and by skip areas of involvement (ie, segments of normal-appearing bowel interrupted by areas of disease).
- The transmural inflammatory nature of Crohn's disease **may lead to fibrosis and strictures and to obstructive** clinical presentations that are not typically seen in patients with ulcerative colitis. Transmural inflammation may also result in **sinus tracts**, giving rise to microperforations and fistula formation.
- Crohn's disease most commonly involves the ileum and proximal colon; however, any part of the gastrointestinal tract may be affected.

Clinical presentation

- Abdominal Pain, diarrhea, weight loss, anorexia , fatigue , perianal pain / discharge.

- Diarrhea associated with CD may have multiple causes including:
  1) Excessive fluid secretion and impaired fluid absorption by inflamed small or large bowel.
  2) Bile salt malabsorption due to an inflamed terminal ileum.
  3) Steatorrhea related to loss of bile salts.
  4) Enteroenteric fistulas causing bypass of portions of absorptive surface area.

Features of transmural inflammation

- **Fistulas**: Transmural inflammation is associated with sinus tracts that may penetrate the serosa and give rise to fistulas.

  Fistulas: tracts or communications that connect two epithelial-lined organs.
- For example, fistulas may connect the intestine
  to bladder (enterovesical),
  to skin (enterocutaneous),
  to bowel (enteroenteric), or
  to the vagina (enterovaginal).

- **Phlegmon/abscess:** may present as a

  phlegmon, (a walled-off inflammatory mass without bacterial infection) that may be palpated on physical examination of the abdomen. Ileal involvement is suggested by a mass in the right lower quadrant.

  Some sinus tracts lead to abscess formation and an acute presentation of localized peritonitis with fever, abdominal pain, and tenderness.

- **Perianal disease** – Symptoms and signs related to perianal disease may occur in up to 40 percent of patients during the course of CD.

Other gastrointestinal features

- Examples include:

1) Oral involvement may present with aphthous ulcers or pain in the mouth and gums.

2) Esophageal involvement may present with odynophagia or dysphagia.

3) Gastroduodenal involvement is seen in up to 15 percent of patients and may present with upper abdominal pain, nausea, and/or postprandial vomiting.

The clinical features of gastroduodenal CD may be similar to those of peptic ulcer disease or gastric outlet obstruction.

The distal antrum of the stomach and duodenum are the most commonly affected upper gastrointestinal (GI) sites in patients with CD.

- **Malabsorption** — Patients with small bowel CD and bile salt malabsorption may present with watery diarrhea and steatorrhea that can lead to protein calorie malnutrition, hypocalcemia, vitamin deficiency (eg, vitamin B12), and metabolic bone disease.

Small bowel disease involving greater than 100 cm of terminal ileum usually results in severe impairment of the enterohepatic circulation of bile salts such that the liver's ability to upregulate de novo bile acid synthesis is inadequate to meet normal physiologic needs for bile production, resulting in fat malabsorption.

Shorter segments of terminal ileal disease (ie, <100 cm) may result in chronic diarrhea, even though it may not result in fat malabsorption, since the bile acids that are not absorbed in the small intestine may stimulate water and electrolyte secretion in the colon (which is called "cholerrheic diarrhea").

Extraintestinal manifestations

- **Arthritis or arthropathy** (The most common extraintestinal manifestation) Primarily involving large joints in approximately 20 percent of patients without synovial destruction, Central or axial arthritis may also occur.
- **Eye involvement** :include uveitis, iritis, and episcleritis,..)
- **Skin involvement :**erythema nodosum and pyoderma gangrenosum Rarely, vulvar involvement.
- **Primary sclerosing cholangitis.**
- **Other hepatobiliary involvement :** often related to IBD medications rather than the disease itself. However, conditions such as pyogenic liver abscess are rarely seen in association with CD.

- **Secondary amyloidosis**
- **Renal stones :**
  Calcium oxalate and uric acid kidney stones can result from steatorrhea and diarrhea.
  Uric acid stones can result from dehydration and metabolic acidosis.
- **Bone loss :** due to glucocorticoid use and impaired vitamin D and calcium absorption
- **Pulmonary involvement :**

Laboratory findings

- Routine laboratory tests may be normal or they may reveal :
  Anemia,
  Elevated white blood cell count,
  Elevated C-reactive protein,
  Electrolyte abnormalities,
  Iron deficiency, vitamin B12 deficiency, and vitamin D deficiency.

- Stool inflammatory markers (fecal calprotectin or lactoferrin) may be elevated due to intestinal inflammation

Differential diagnosis

- **Infectious colitis**
- **Ulcerative colitis** (when involves the colon)
- **Diverticular colitis**
- **Celiac disease**
- **Irritable bowel syndrome**

The typical workup for most patients in whom CD is suspected includes:

- Laboratory studies including blood tests and, for patients with diarrhea, stool studies.
- Small bowel imaging (usually magnetic resonance enterography [MRE] where available).
- Colonoscopy with intubation of the terminal ileum, including mucosal biopsies. During colonoscopy, biopsies are obtained from the right colon, left colon, and rectum even if endoscopically normal in appearance to assess for histologic evidence of inflammation.

  Granulomas may be noted in up to 30% of patients with CD and this histologic finding supports but is not required to establish the diagnosis.

Typical granuloma of Crohn disease

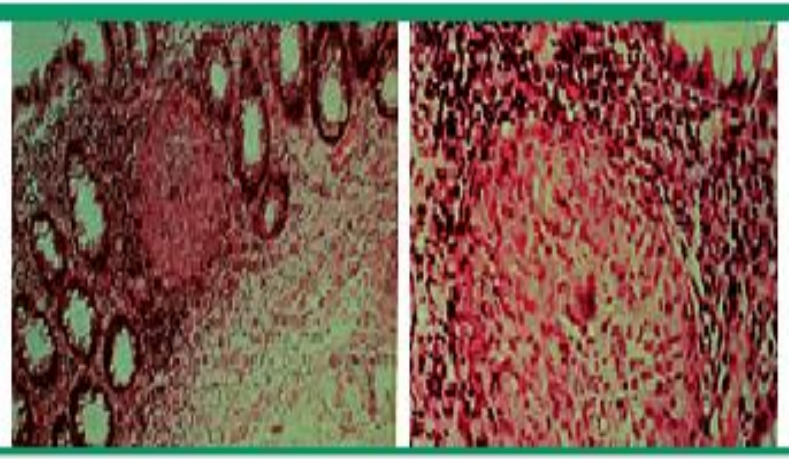

Light micrographs showing a granulomatous lesion that is diagnostic of Crohn disease. Low and high power views show a central giant cell surrounded by epitheliod cells and rimmed by lymphocytes.

Courtesy of the American Gastroenterological Association©. This slide cannot be downloaded but may be purchased as part of a set from the AGA.

UpToDat

Crohn disease

Small bowel ulceration as seen during capsule endoscopy.

Courtesy of Given Imaging, Inc.

UpToDate®

Ileocecal fistulae in Crohn disease

Small bowel follow through examination demonstrates nodular thickening of the terminal ileal mucosal folds in a patient with Crohn disease (arrow). Several fistulae extend from the terminal ileum to the adjacent cecum (arrowheads).

Courtesy of Jonathan Kruskal, MD, PhD.

UpToDate®

Endoscopic findings in Crohn disease

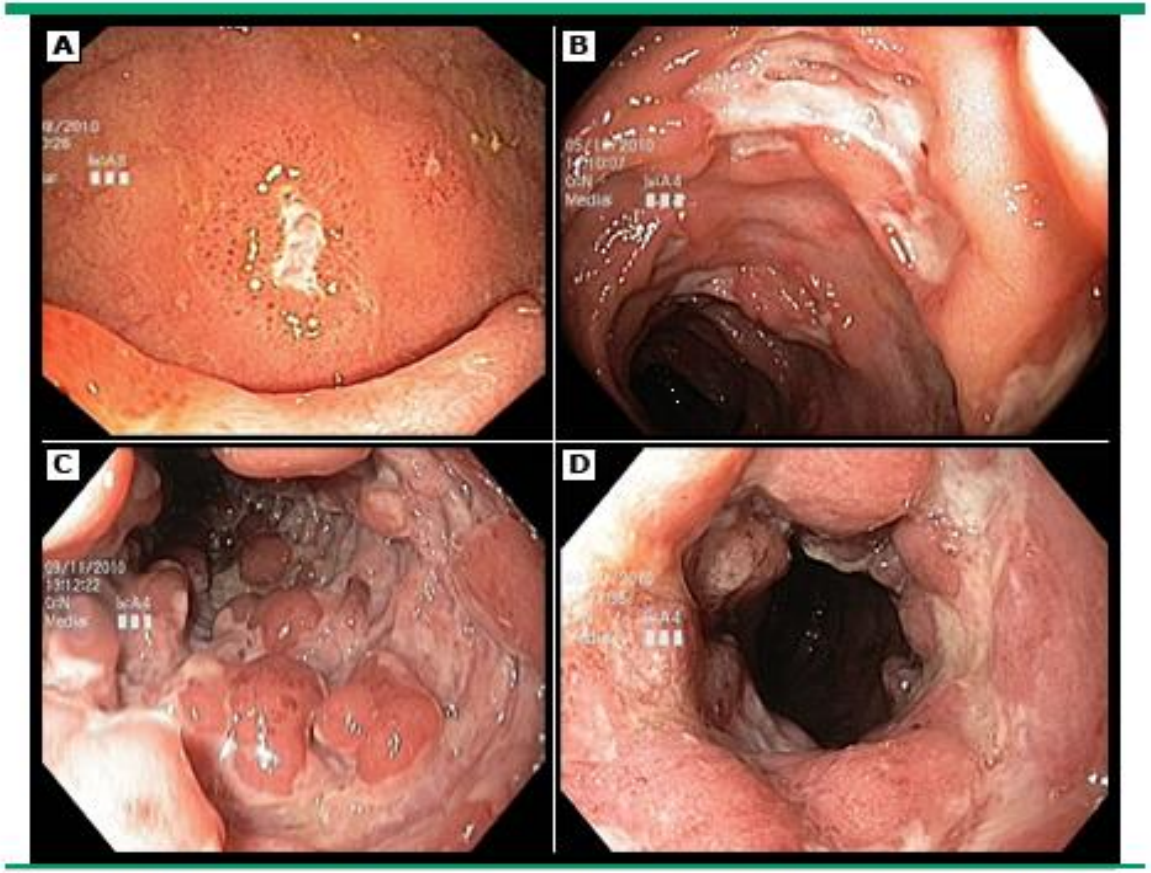

The dominant endoscopic feature in Crohn disease is the presence of ulcerations. Endoscopic findings in Crohn disease include: aphthous ulcers, which are the earliest lesions seen in Crohn disease (panel A); large ulcers interspersed with normal mucosa, which are typical for the segmental distribution of Crohn disease (panel B); a cobblestone appearance that is characterized by nodular thickening, with linear or serpiginous ulcers (panel C); and strictures due to fibrosis (panel D).

Courtesy of Paul Rutgeerts, MD, PhD, FRCP.

UpToDate®

- **Risk factors for progressive disease include** :

Age <40 years

Tobacco use

Perianal or rectal involvement

Glucocorticoid-requiring disease

- **Risk of surgery** : The 10-year risk of surgical resection for CD is nearly 50 percent

Cancer risk

- CRC
- Squamous cell carcinoma of the anus and skin
- Adenocarcinoma of the small bowel.
- Duodenal neoplasia.
- Testicular cancer, and
- Leukemia have all been reported in CD, although the strength of these associations is unclear.

- In addition, patients receiving thiopurine therapy for IBD had an increased risk of developing lymphoproliferative disorders

TABLE 10-2. Ulcerative Colitis vs. Crohn's Disease

	Ulcerative Colitis	Crohn's Disease
Pathology	▪ Inflammation of the mucosa only (exudate of pus, blood, and mucus from the "crypt abscess") ▪ Always starts in rectum (up to one third don't progress) ▪ Limited to colon and rectum	▪ Inflammation involves all bowel wall layers, which is what may lead to fistulas and abscess ▪ Rectal sparing in 50% ▪ May affect mouth to anus
Diagnosis	▪ Continuous lesions ▪ Rare ▪ Lead pipe colon appearance due to chronic scarring and subsequent retraction and loss of haustra	▪ Skip lesions: Interspersed normal and diseased bowel ▪ Aphthous ulcers ▪ Cobblestone appearance from submucosal thickening interspersed with mucosal ulceration
Complications	▪ Perforation ▪ Stricture ▪ Megacolon ▪ Cancer	▪ Abscess ▪ Fistulas ▪ Obstruction ▪ Cancer ▪ Perianal disease

Treatment

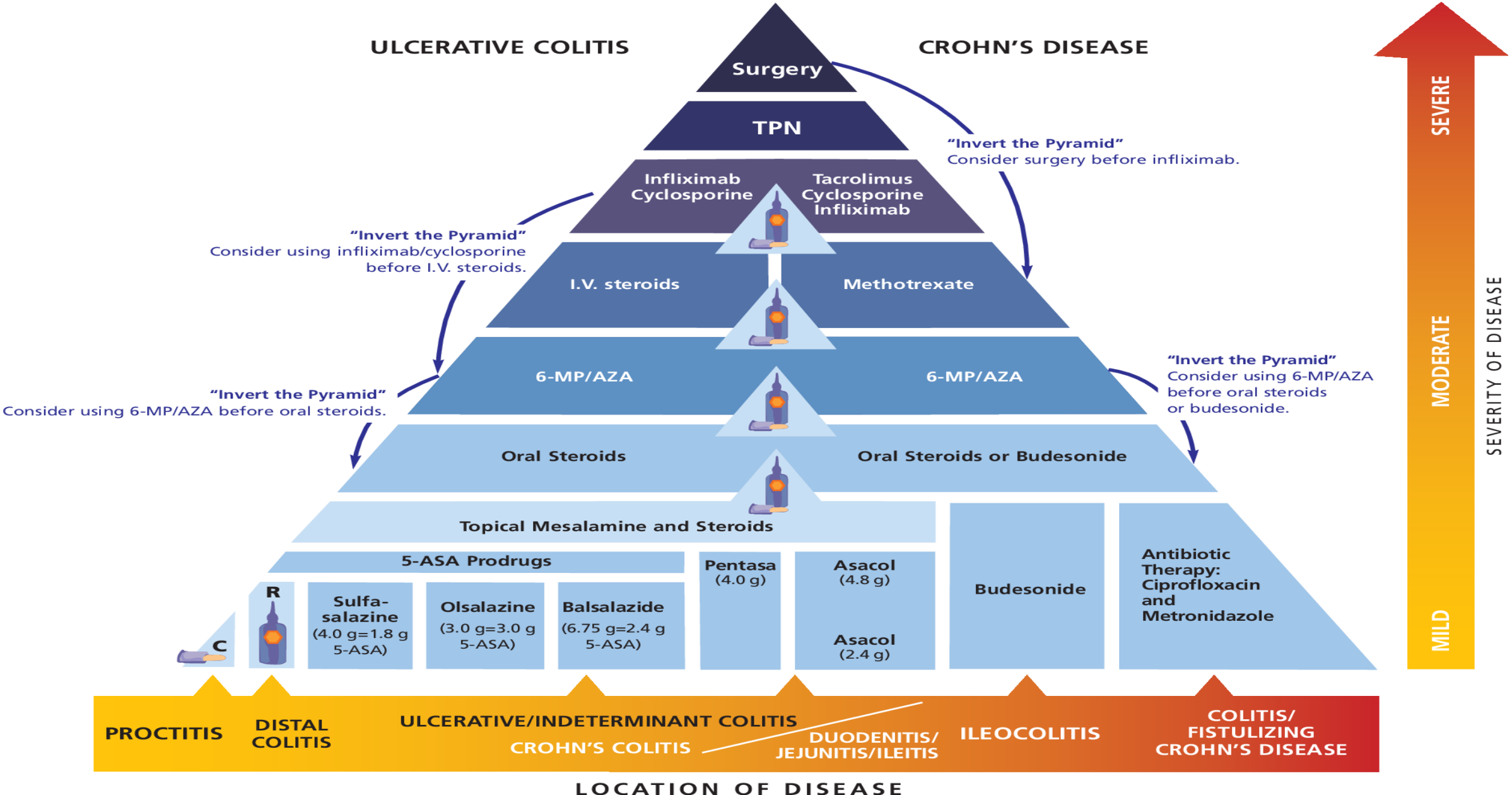
ULCERATIVE COLITIS
CROHN'S DISEASE
Surgery
TPN
Infliximab
Cyclosporine
Tacrolimus
Cyclosporine
Infliximab
I.V. steroids
Methotrexate
6-MP/AZA
6-MP/AZA
Oral Steroids
Oral Steroids or Budesonide
Topical Mesalamine and Steroids
5-ASA Prodrugs
C
R
Sulfa-salazine (4.0 g=1.8 g 5-ASA)
Olsalazine (3.0 g=3.0 g 5-ASA)
Balsalazide (6.75 g=2.4 g 5-ASA)
Pentasa (4.0 g)
Asacol (4.8 g)
Asacol (2.4 g)
Budesonide
Antibiotic Therapy: Ciprofloxacin and Metronidazole
"Invert the Pyramid"
Consider surgery before infliximab.
"Invert the Pyramid"
Consider using infliximab/cyclosporine before I.V. steroids.
"Invert the Pyramid"
Consider using 6-MP/AZA before oral steroids.
"Invert the Pyramid"
Consider using 6-MP/AZA before oral steroids or budesonide.
SEVERE
MODERATE
MILD
SEVERITY OF DISEASE
PROCTITIS
DISTAL COLITIS
ULCERATIVE/INDETERMINANT COLITIS
CROHN'S COLITIS
DUODENITIS/ JEJUNITIS/ILEITIS
ILEOCOLITIS
COLITIS/ FISTULIZING CROHN'S DISEASE
LOCATION OF DISEASE

INDICATIONS FOR OPERATIVE MANAGEMENT

- Bowel perforation.
- Intra-abdominal, retroperitoneal, or abdominal wall abscess refractory to nonoperative management.
- Gastrointestinal bleeding refractory to nonoperative management.
- Symptomatic fibrotic stricture causing intestinal obstruction.
- Enteric fistula refractory to medical therapy.
- Small bowel or colorectal cancer arising from longstanding Crohn disease.
- Persistent inflammation causing symptoms refractory to medical therap.
- Growth retardation in children with Crohn disease

Thank You